Histol Histopathol (2008) 23: 87-100
DOI: 10.14670/HH-23.87

http://www.hh.um.es

Histology and Histopathology
Cellular and Molecular Biology

Effects of sediment sorbed linear alkylbenzene sulphonate on juveniles of the Senegal sole, *Solea senegalensis*: Toxicity and histological indicators

M. Hampel*, J.B. Ortiz-Delgado, C. Sarasquete and J. Blasco
Instituto de Ciencias Marinas de Andalucía (CSIC), Campus Río San Pedro, Puerto Real, Spain
*Present address: Institute of Aquaculture, University of Stirling, FK9 4LA Stirling, UK

Summary. Many synthetic organic substances, including surfactants, tend to be sorbed on suspended solids and to accumulate finally on bottom sediments, where benthic communities may be exposed to them. Concentrations of Linear Alkylbenzene Sulphonates (LAS) have been detected in estuarine and coastal sediments, presenting wide concentration ranges depending on the presence of treatment facilities, hydrodynamic conditions, organic matter content, etc.

Senegal sole, *Solea senegalensis,* larvae (40 days posthatching; dph) were exposed to increasing concentrations of LAS spiked sediments, comprised between 0.37 and 880.78 mg LAS·kg^{-1} during 30 days. The obtained results showed that survival of exposed larvae was not significantly affected at environmentally relevant concentrations, the LC50 value being obtained after 30 days 876.46 mg·kg^{-1}. However, the histological and histopathological analyses carried out in target organs revealed, that first alterations from the normal pattern were observed at concentrations of 222.66 mg·kg^{-1}, presenting effects such as blood extravasation and hyperplasy of the lamellar epithelium in gills, increase of inter-myotomal spaces of the skeletal musculature and edematous separation of the skin from epidermis. At the highest exposure concentrations (755.27 and 880.78 mg LAS·kg^{-1}), shrinkage of hepatocytes, nuclear pycnosis and blood stagnation are observed in the liver, degeneration of pancreatic cells, reduction of hemocytopoietic tissue in the kidney and vacuolisation of intestinal enterocytes was observed at histological level, as well as severe separation of the epidermis from the underlying tissues. Simultaneously, a significant increase of the wet weight with exposure concentration was observed in the test organisms.

Offprint requests to: Miriam Hampel, Institute of Aquaculture, University of Stirling, FK9, 4LA Striling, UK. e-mail: miriam.hampel@stir.ac.uk

Key words: *Solea senegalensis*, Histology, Linear alkylbenzene sulphonates, Sediment, Toxicity.

Introduction

Marine environments may act as a permanent sink for substances that tend to sorb on suspended solids and sediments and may be accumulated to concentrations at which they may exert significant toxic effects (SETAC, 1993). The degree of association of LAS to the sediment compartment depends mainly on its degree of hydrophobicity and the organic matter content of the sediment determining fundamentally the fraction of the compound related with the water column and the sorbed fraction (Urano et al., 1984; Matthijs and De Hanau, 1985; Hand and Williams, 1987). Pollution of aquatic habitats may induce pathological changes in fish (Malins et al., 1985; Myers et al., 1990, 1998; Vethaak et al., 1992, 2002; Collier et al., 1998; Matthiessen et al., 1998). Histology, as an indicator of the effects of exposure to contaminants, represents a very useful tool to assess the degree of pollution, particularly for sublethal and chronic effects of xenobiotics. The exposure of fish to chemical contaminants is likely to induce a number of histological disorders in different organs and tissues (Sindermann, 1979; Bucke et al., 1996; Ortiz-Delgado and Sarasquete, 2004).

Linear Alkylbenzene Sulphonates (LAS) are the most employed surfactants in the formulation of laundry and personal cleaning products, with an annual global production rate of 4 million metric Tons (HERA-LAS, 2004). The surfactant molecule is composed of a hydrophobic moiety, an alkyl chain of between 10 and 14 carbon atoms and a hydrophilic part composed of a benzene ring and a sulphonate group. Due to these molecular characteristics, LAS tends to be sorbed onto sediment particles once discharged into receiving waters.

Even if in waste water treatment plants LAS is removed in up to 99%, certain amounts of this compound may reach rivers and coastal waters, and finally the sediment (HERA-LAS, 2004), where environmental concentrations have been analysed by various authors (Takada and Ishiwatari, 1991; Takada et al., 1992a,b; González-Mazo et al., 1997,1998; Lillebaelt Report, 1998; Marcomini et al., 2000). As a consequence, benthic organisms may be exposed to different levels of LAS associated to the sediment. These exposure concentrations may not be lethal for the affected species, but may affect internal functions and structures which under chronic exposure conditions could have effects on the effectiveness of vital functions and processes, such as resistance to environmental and competitive stress, reproduction, growth, etc (Duft et al., 2003). In order to determine the levels at which alterations may be observed, organisms may be exposed to spiked sediments. This procedure allows the determination of produced effects exclusively due to the studied compound as other sources of contamination are excluded (EU TGD, 2003). The knowledge about action patterns of individual compounds facilitates, at continuation, the evaluation of effects that may appear in mixtures of compounds and so to determine possible additive or synergic processes.

In aqueous phase, LAS has shown to induce peri-yolk sac edema in neonate (<24h) larvae of the seabream, *Sparus aurata*, after 72h at concentrations of 0.2 $mg \cdot L^{-1}$. Higher exposure concentrations (up to 1.0 $mg \cdot L^{-1}$) provoked disorganisation of the nervous system, trunk musculature and trophoblastic syncytium as well as in the digestive epithelium (Hampel et al., 2004).

The Senegal sole, *Solea senegalensis* (Kaup, 1858), is a flatfish with an original habitat in the West Atlantic, from Senegal up to La Rochelle (France), where it is submitted to extensive aquaculture exploitation. After an incubation time of approximately 48 hours, a perfectly symmetric, pelagic larva is released from the egg into the medium. After between 11 and 19 days, the larva transforms into an asymmetric individual by metamorphosis moving the left eye towards the right side. From this moment on, the organism adopts a benthic life with the left side in contact with the bottom sediment and feeding from benthic organisms such as crustaceans and polychaets (Cabral, 2000). The histological development and histochemical characteristics of this species were largely described (Ribeiro et al., 1999; Sarasquete et al., 1996, 1998, 2001; Piñuela et al., 2004; Ortiz-Delgado et al., 2006). For this reason and due to its relatively easy supply by local aquaculture facilities in the Iberian Peninsula (Dinis et al., 1999), this species was selected to evaluate the lethal and sublethal effects of sediment associated LAS exposure. In the present study, 45-day-old larvae of the Senegal sole, *Solea senegalensis*, were exposed to increasing portions of LAS spiked sediment to evaluate the effect of this compound at histopathological level.

Materials and methods

Spiking of natural sediments with LAS

Experimental sediments were collected in areas of the Bay of Cádiz, Spain, which are known to be far from urban and industrial discharge points in order to reduce to a maximum initial LAS contamination. The quality parameters were measured in these reference sediments (i.e. pH; organic carbon) and the overlying water column once the experiment has started. The spiking procedure of the sediments was adapted to the protocol proposed by Cassellato et al. (1992). The surfactant was a commercial LAS mixture (CAS Nr. 68411-30-3, supplied by Petroquímica Española S.A., PETRESA, Spain) with an average chain length of 11.6 carbon atoms and homologue distribution of C10 to C14 of 10.9; 35.3; 30.4; 21.2 and 1.1%, respectively.

The substrate was washed gently with distilled water and dried at 70°C. LAS concentration in these untreated sediments was 0.54 $mg \cdot kg^{-1}$. The material was saturated for 24 hours under continuous agitation with a highly concentrated commercial LAS mixture. After finishing the spiking procedure, the sediment was washed once more with distilled water in order to eliminate possible LAS excesses in the sediment and finally dried again at 70°C.

Analysis of effective LAS concentrations in the sediment

Sediment samples were maintained at -18°C and afterwards lyophilized. LAS concentrations were analysed after Soxhlet extraction during 6 hours. After evaporation of the solvent and dissolution in 100 mL Milli-Q, the extract was subjected to solid phase extraction passing it through a C18 column (Bond Elut, C18, Varian) and subsequently through anionic exchange column SAX (Supelco, Bellefonte, PA,USA). The resulting volume was evaporated, the precipitate dissolved in 1 mL MeOH:H_2O (80:20 v/v) and stored at -18°C until LAS analysis by high performance liquid chromatography (HPLC, HP 1050) with fluorescence detector (λex = 225 nm, λem = 295 nm) as described by León et al. (2000). Obtained concentration values are referred to as dry weight.

Exposure of organisms

The exposure protocol was adapted to the guidelines proposed by the US EPA (1994) and Ingersoll and Nelson (1990). Increasing LAS concentrations were achieved by mixing different proportions of LAS spiked and untreated sediment (SETAC, 1993). Due to the preference of this organism to sandy substrate, the total volume of 0.5 kg experimental sediment was composed of 0.25 kg unspiked sand and 0.25 kg spiked sediment which were gently homogenised. The latter 0.25 kg of sediment were composed of different portions of spiked and not spiked substrate in order to achieve increasing

exposure concentrations which were comprised between 0.54 and 880.78 mg·kg^{-1} dry weight. The organisms, supplied by IFAPA (CIFPA El Toruño, El Puerto de Santa María, Cadiz, Spain/South Iberian Peninsula), were exposed during 30 days under continuous flow through conditions, photoperiod 12 hours light : 12 hours darkness and temperature of 25°C±1°C. Water supply was about 18L·h^{-1} of clean seawater without addition of LAS. After maintaining the system 24 hours without organisms to eliminate possible LAS excesses, 30 juveniles were placed in each vessel. Additionally, a sample of 30 organisms was taken at the beginning of the experiment in order to determine median individual dry and wet weight for the comparison of these parameters with those estimated at the end of the assay. The organisms were exposed to five increasing concentrations. Assays were performed in duplicate and control experiments were carried out simultaneously.

The organisms were fed daily with 100 mL of a solution containing *Artemia salina nauplii* (<24h) of approximately 200000-400000 inds/L (Dinis et al., 1999) for which the water supply was interrupted for 3 hours in order to avoid evacuation of the food through the sink. *Artemia salina* cysts were incubated in 1,5L capacity recipients with photoperiod 12:12 hours light:darkness and ambient temperature, 24 hours previous to their addition into the aquariums. Mortality control was performed daily and dead individuals were removed from the vessel. Obtained mortality data for each assay were adjusted employing generalised linear models (GLM) using the statistical software GLMstat (http://www.glmstat.com/) and LC50 values at different moments of the experiment were calculated as described by Kerr and Meador (1996).

Once past the exposure time of 30 days, ten surviving fish per treatment were anaesthetized with phenoxyethanol and fixed in 0.1M formaldehyde-phosphate buffer at pH 7.2 at least for 24 hours and embedded in paraffin wax for the analysis of histopathologic effects. Due to the small size of the juvenile it was considered to fix the whole organism. Some of the bigger ones were dissected and different organs extracted before fixation in order to avoid autolysis phenomena. Preparations were cut into 6 μm-thick slices and sections were then stained with haematoxylin-eosin and haematoxylin-V.O.F. (light green-orangeG-acid fuchsin) (Gutiérrez, 1990) for histomorphological observations under light microscopy. Additionally, final individual median wet and dry weights were determined at the end of the experiment in order to determine growth of the organisms during the exposure time.

Results

Acute toxicity

The sediment and water characterising parameters are provided in table 1. LAS concentrations in the experimental sediments (n=2), to which juveniles of *S. senegalensis* were exposed, were comprised between 0.54±0.23 (SD) and 880.78±191.39 (SD) mg·kg^{-1} in the control and the highest exposure concentration, respectively (Table 2). The obtained LC50 value after 30 days exposure was 876.46±158.90 mg·kg^{-1}. Mortality in control experiments was 5% fulfilling the reliability criteria proposed by the OECD (Wheeler et al., 2002).

At the highest exposure concentrations (880.78 and

Table 1. Physico-chemical parameters, such as organic carbon (%O.C.), grain size composition (-% fine sand-), elemental analysis (% C, H, N) and pH in the reference sediment and dissolved oxygen (%D.O.), salinity and pH of the overlying water column.

Sediment					
O.C. (%)	% < 63μm	C (%)	H (%)	N (%)	pH
0.618±0.015	22	1.19±0.42	1.06±0.13	0.06±0.01	7.3±0.1
Water					
D.O. (%)	Salinity	pH			
60-100	37±1	7.5±0.1			

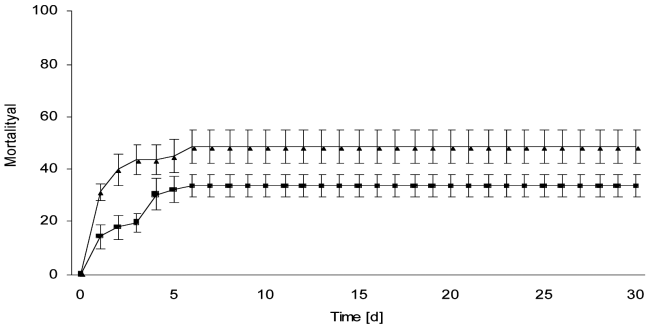

Fig. 1. Mortality percentage (± SD) versus exposure time for the two highest exposure concentrations 755.27 (squares) and 880.78 (triangles) mg·kg^{-1} dry weight.

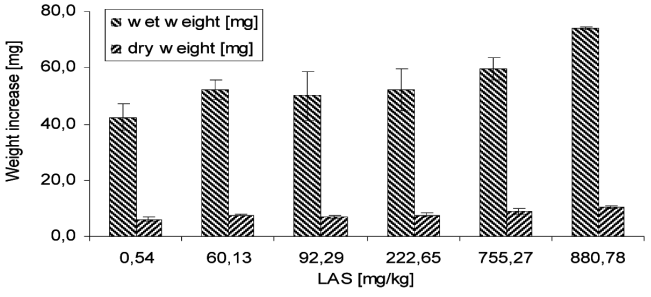

Fig. 2. Increase of median dry and wet weight (Weightt=30-Weightt=0) of organisms at each exposure concentration along the experiment.

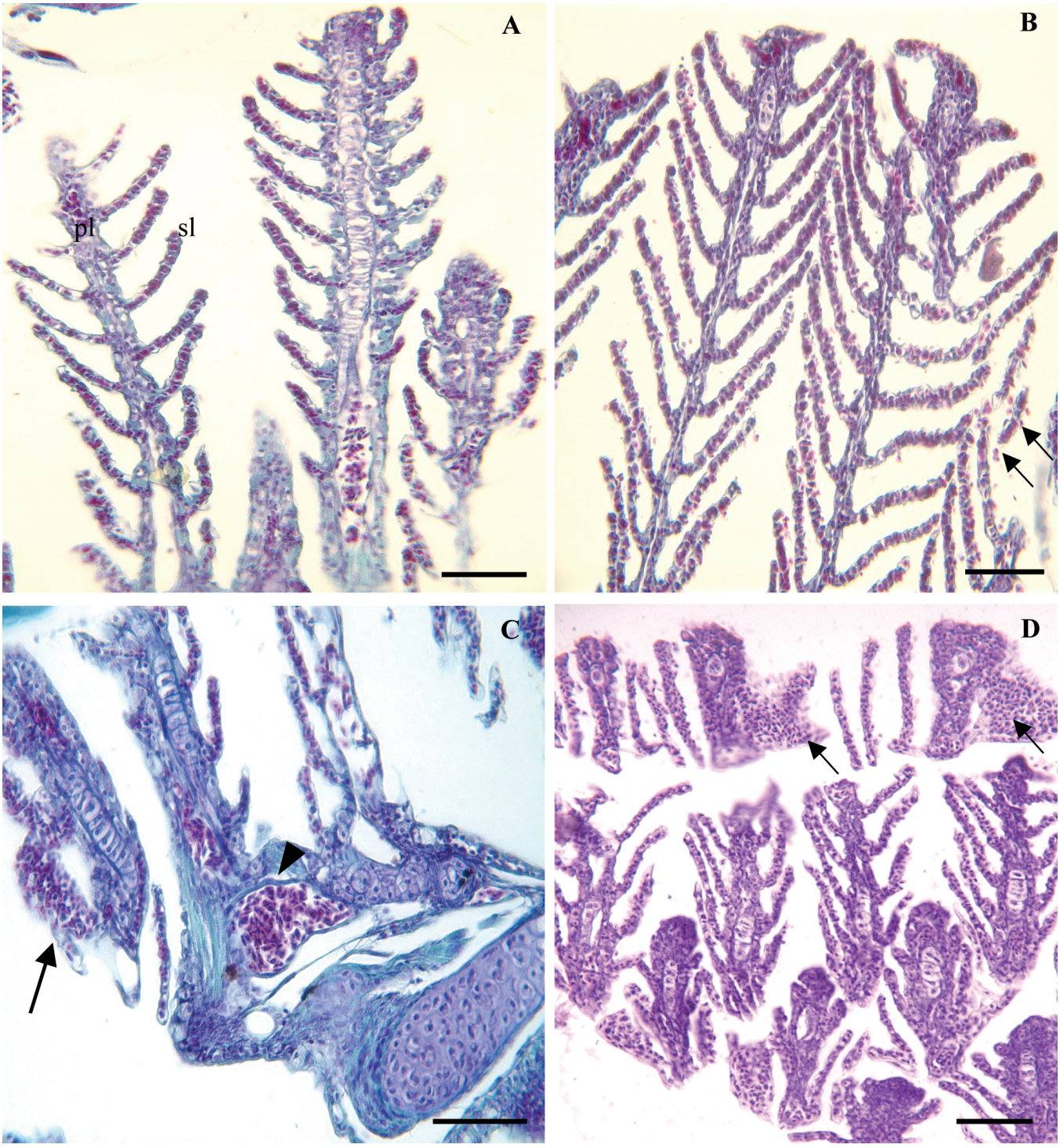

Fig. 3.A. Transversal sections of gills from control specimens showing basic features of primary (pl) and secondary lamellae (sl). Histological sections of gills of treated organisms **(B)** and **(C)** 222.65 and **(D)** 880.78 mg·kg^{-1} treatments at day 30. Blood extravasation (arrows) **(B)**, hyperplasy of the lamellar epithelium (arrows) and blood stagnation (arrowhead) (**C and D**) are detected in exposed specimens H&VOF (A to C) and H&E (D) staining. Scale bar: 50 μm

755.27 mg·kg^{-1}), the test organisms showed a clear tendency to avoid contact with the sediment after being transferred into the aquariums, maintaining themselves within the water column by active swimming movements. However, this activity was not possible to maintain by the organisms, and finally they adopted their typical position on the sediment surface. At this exposure concentration, a relatively high mortality was observed during the first days. However, approximately after day 6 of exposure, no more mortality was observed and mortality percentages maintained constant during the rest of the assay (Fig. 1A, B). This latter phenomenon was also observed at lower exposure concentrations, and mortality at the two lowest concentrations was not significantly different from that observed in the control assay.

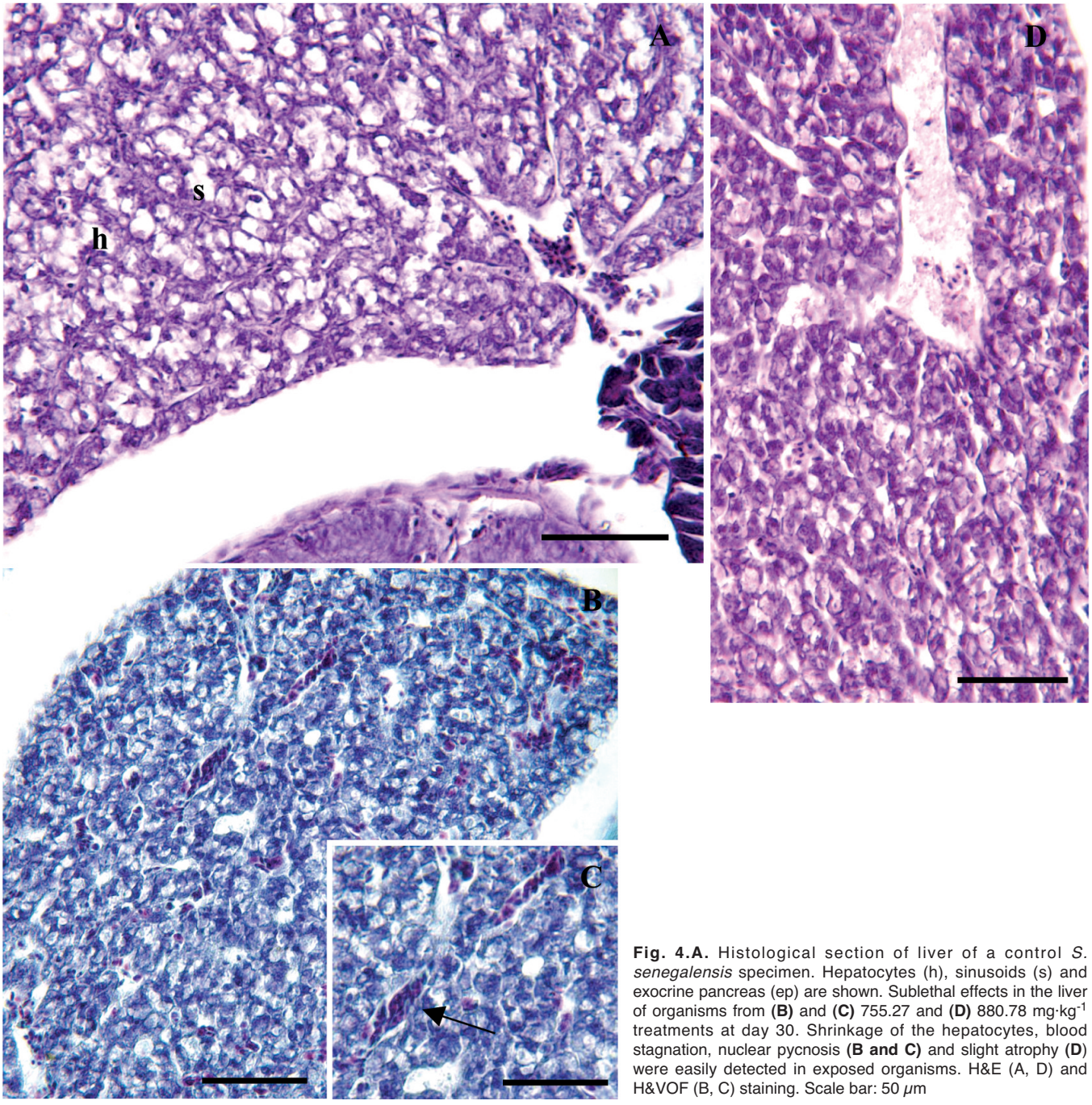

Fig. 4.A. Histological section of liver of a control *S. senegalensis* specimen. Hepatocytes (h), sinusoids (s) and exocrine pancreas (ep) are shown. Sublethal effects in the liver of organisms from **(B)** and **(C)** 755.27 and **(D)** 880.78 mg·kg^{-1} treatments at day 30. Shrinkage of the hepatocytes, blood stagnation, nuclear pycnosis **(B and C)** and slight atrophy **(D)** were easily detected in exposed organisms. H&E (A, D) and H&VOF (B, C) staining. Scale bar: 50 μm

Figure 2 represents the increase in dry and wet weight (y axis) during the 30 days of the experiment at the different exposure concentrations (x axis). Both dry and wet weight increase with exposure time, being the increase in wet weight much more pronounced than in dry weight when increasing the exposure concentration. At the same time, an increase in body weight (mg dry and wet weight) in the exposed organisms was observed frequently in comparison with the control organisms.

Histological approach

Fig. 3 shows gills from control treatment (Fig. 3A) and under the different increasing exposure concentrations (Fig. 3B-D). Gills from control treatments show regular disposition of primary filaments (pl) and secondary lamellae (sl) where respiratory gas exchange takes place by diffusion. Each primary filament consists of a central cartilage covered by connecting tissue which contains the afferent and efferent blood vessels (Arellano and Sarasquete, 2005). First alterations from control gills are observed at LAS concentrations of 222.66 mg·kg^{-1} (Fig. 3B, C) presenting blood extravasation with accumulation of blood cells in the inter-lamellar space in affected secondary lamellae (Fig. 3B, arrows), hyperplasy of the lamellar epithelium to be observed by obliteration of the inter-lamellar space and fusion with the adjacent lamellae (arrow), and blood stagnation of vessels in the gill arch (arrowhead) (Fig. 3C). At the highest exposure concentration (880.78 mg LAS·kg^{-1} dry weight), an increased hyperplasia of the respiratory epithelium (arrows) and fusion of lamellae is observed (Fig. 3D).

In the liver (Fig. 4) the hepatic parenchyma of control organisms shows regular distribution of hepatocytes disposed in cords of two cells around the vascular system (sinusoids) (Fig. 4A). The hepatocytes are polygonal-shaped, presenting a granular and vacuolated acidophilic cytoplasm and an eccentric nucleus, which presents a prominent nucleolus. At exposure concentrations of 755.27 mg·kg^{-1}, shrinkage of hepatocytes and nuclear pycnosis (Fig. 4B,C) and blood stagnation with congestion of sinusoids (Fig. 4C, arrow)

Table 2. LAS exposure concentrations (mg·kg^{-1} dry weight ± standard deviation).

Exposition	[LAS]
Control	0.54±0.23
1	60.13±49.47
2	92.29±32.31
3	222.66±64.52
4	755.27±19.32
5	880.78±191.39

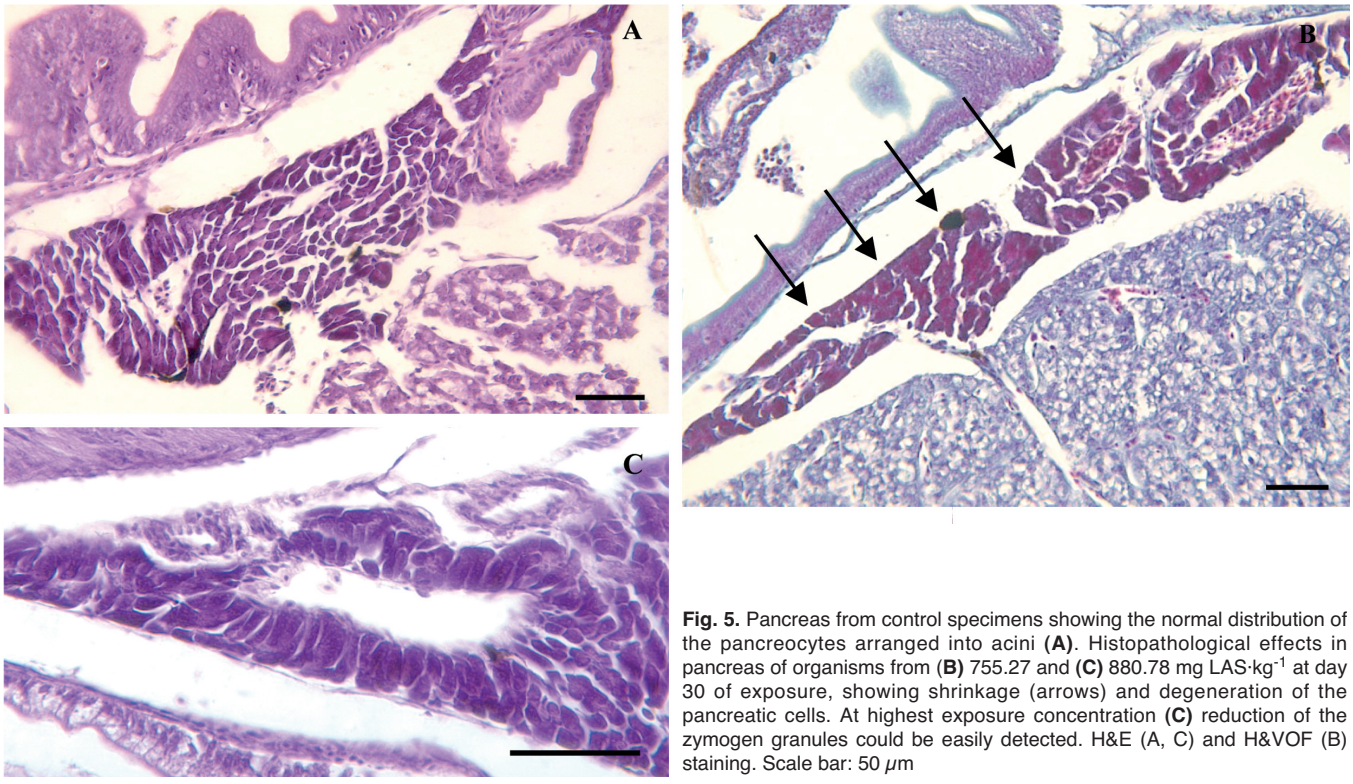

Fig. 5. Pancreas from control specimens showing the normal distribution of the pancreocytes arranged into acini **(A)**. Histopathological effects in pancreas of organisms from **(B)** 755.27 and **(C)** 880.78 mg LAS·kg^{-1} at day 30 of exposure, showing shrinkage (arrows) and degeneration of the pancreatic cells. At highest exposure concentration **(C)** reduction of the zymogen granules could be easily detected. H&E (A, C) and H&VOF (B) staining. Scale bar: 50 μm

occurs. At the highest exposure concentration hepatocytes are clearly affected showing slight atrophy, or cell volume reduction, with increasing cytoplasmic basophilia (Fig. 4D).

Pancreatic structures (Fig. 5), with glandular acini that compose the exocrine portion of the organ, are disposed in a regular way, diffusely spread in the fat of the abdominal cavity under non-contaminated conditions. These glands are formed by a compact collection of pancreatic cells -acini- with dark basophilic cytoplasm containing a large number of acidophilic granules which contain zymogen (Fig. 5A). At higher LAS concentrations (755.27 $mg \cdot kg^{-1}$), the exocrine pancreas (Fig. 5B) presents slight shrinkage and degeneration of the pancreatic cells (arrow) in comparison with control organisms. At highest exposure concentrations, slight disorganization of the acini, as well as a reduction of the zymogen granules can be detected (Fig. 5C).

In the excretory portion of *S. senegalensis* kidney (Fig. 6), like in other marine teleosts, different sections of renal tubules can be observed (Fig. 6A), which are formed generally by a single layer of cuboidal epithelial cells and a densely arranged microvilli in the tubular

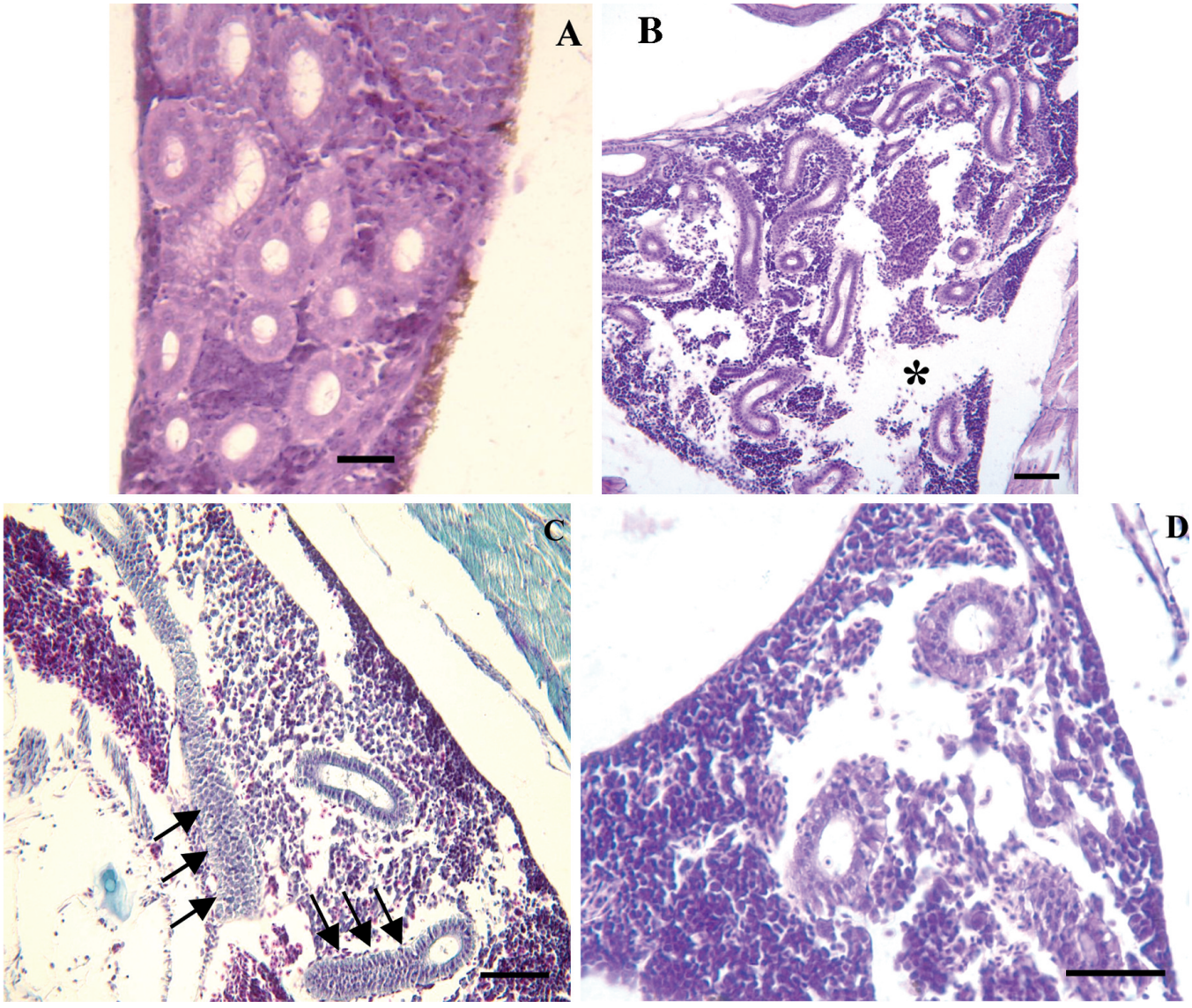

Fig. 6.A. Exocrine portion of kidney from *S. senegalensis* control specimens showing different sections of renal tubules embedded into hematopoietic tissue. Sublethal effects in kidney of organisms from **(B)** and **(C)** 222.65 $mg \cdot kg^{-1}$ and **(D)** 880.78 $mg \cdot kg^{-1}$ treatments at day 30. Note loss of interstitial haematopoietic tissue (asterisk) as well as epithelial hyperplasia with luminal occlusions (arrows). H&E (A, B and D) and H&VOF (C) staining. Scale bar: 50 μm

lumen. These tubules are embedded in an interstitial lymphoid -hematopoietic- tissue. In organisms exposed to intermedian LAS concentrations (222.66 mg·kg^{-1}), the excretory portion of the kidney (Fig. 6B) presents a moderate loss of the interstitial haematopoietic tissue (asterisk), as well as slight epithelial hyperplasia (Fig. 6C) with luminal occlusion (arrows). The interstitial haemocytopoietic tissue of the kidney is even more reduced at the highest exposure concentrations (Fig. 6D).

In the digestive tract, (Fig. 7) intestinal folds present uniform disposition of the mucosal enterocytes under control conditions (Fig. 7A) forming a simple epithelium of cylindrical cells with numerous goblet cells. At higher LAS concentrations, the intestinal mucosa (Fig. 7B) does not present apparent alterations. However, at highest exposure concentrations (880.78 mg·kg^{-1}), the cytoplasm of the intestinal enterocytes shows vacuolisation (neutral lipids) (Fig. 7C).

The mucosa of the stomach (Fig. 8) is composed of a simple epithelium of cubic cells with numerous gastric glands (asterisk) placed in the submucosa (Fig. 8A). At higher LAS concentrations (222.65 mg·kg^{-1}), in the gastric mucosa (asterisk) certain epithelial hyperchromatism can be observed (Fig. 8B). However, the gastric glands that start to develop around the first month of larval life do not show apparent histological alterations (Fig. 8C).

In the tegument (Fig. 9), which in control organisms of *S. senegalensis* is developed regularly (Fig. 9A), the epidermis is a stratified squamous epithelium constituted by cubic germinative or basal cells that become more

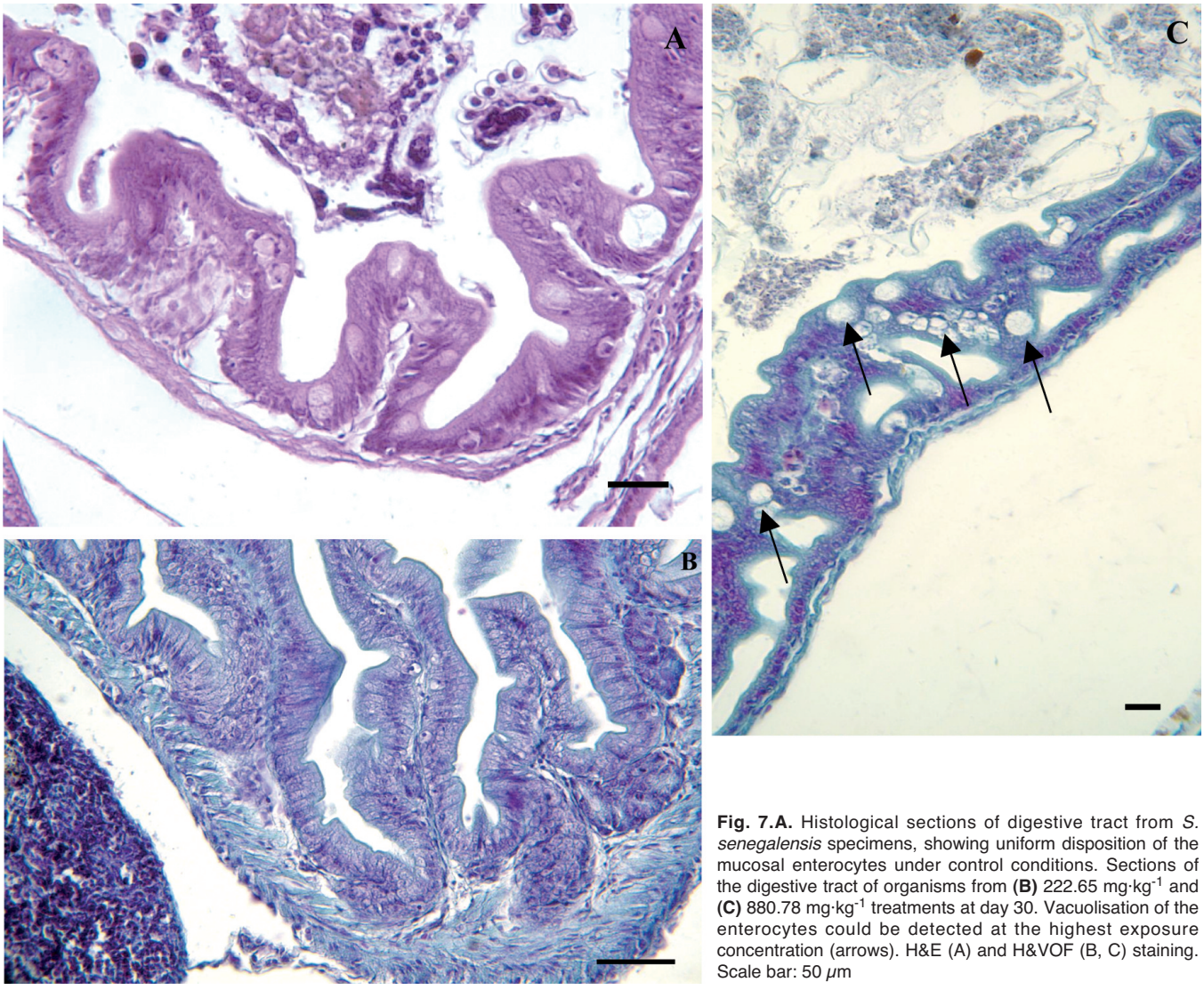

Fig. 7.A. Histological sections of digestive tract from *S. senegalensis* specimens, showing uniform disposition of the mucosal enterocytes under control conditions. Sections of the digestive tract of organisms from **(B)** 222.65 mg·kg^{-1} and **(C)** 880.78 mg·kg^{-1} treatments at day 30. Vacuolisation of the enterocytes could be detected at the highest exposure concentration (arrows). H&E (A) and H&VOF (B, C) staining. Scale bar: 50 μm

and more squamous when approximating the surface. Enclosed between epithelial cells, mucus cells may eventually be observed, as well as other types of secretory cells. The epidermis lies in a basal lamina overlying a considerable dermal space in which melanophores may be observed in its upper region. The skeletal musculature (Fig. 10) showed a regular disposition of myomers and collagen myosepts, forming together with the skin a uniform structure (Figs. 9A, 10A). However, when increasing the LAS load in the sediments, the inter-myotomal spaces of the musculature (Fig. 10B) are moderately increased (asterisk), and slight edematous separation of the skin from the epidermis is observed (Fig. 9B). At highest LAS concentrations (Fig. 10C), the trunk musculature shows severe shrinkage of the myomers with an increase of the inter-myotomal spaces in comparison with musculature of control organisms (Fig. 10B). Transversal sections of skin and musculature also reveal an increase of the intermyotomal spaces, as well as an evident edematous separation of the epidermis from the underlying dermal tissue (Fig. 9C).

Discussion

Toxicity tests are tools to evaluate the potential hazard of contaminants that are released into the environment for the existing organisms. The information obtained in this kind of assay allows the establishment of admissible threshold concentrations in the different environmental departments that guarantee that the existing organisms are not affected even under long term exposition (EU TGD, 2003).

From our experiments with *S. senegalensis* exposed to different LAS concentrations, the obtained LC50 value of 876.46 mg·kg^{-1} is comprised between the values obtained by other authors in similar assays. In this context, Marin et al. (1994) studied the effects of sediment sorbed LAS concentrations on the bivalve mollusc *Mytilus galloprovincialis*. These authors did not observe any effects in filtration rate and survival at exposure concentrations up to 132.04 mg·kg^{-1}, indicating good tolerance of the test organism towards these contaminant levels. More recently, Comber et al. (2006)

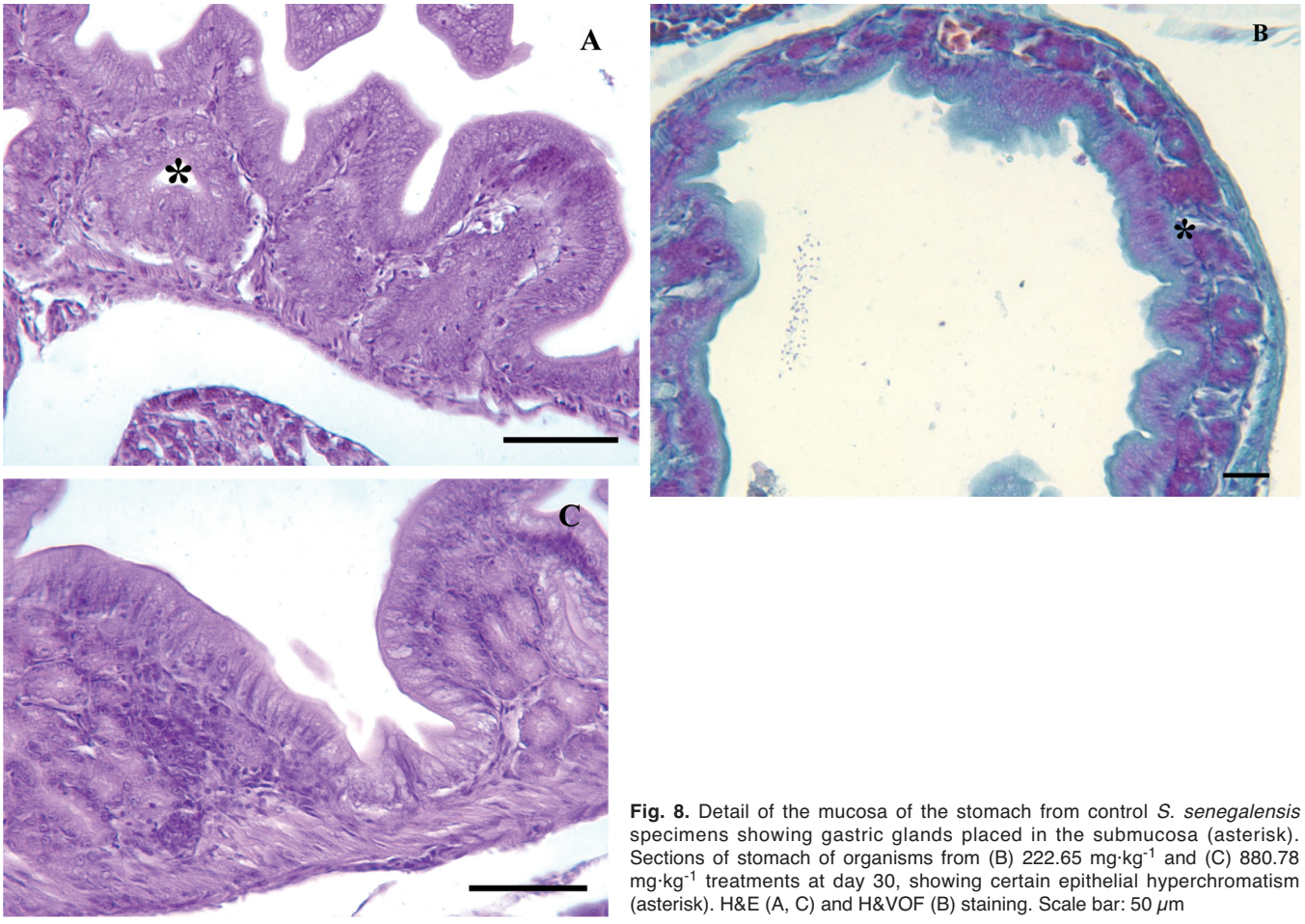

Fig. 8. Detail of the mucosa of the stomach from control *S. senegalensis* specimens showing gastric glands placed in the submucosa (asterisk). Sections of stomach of organisms from (B) 222.65 mg·kg^{-1} and (C) 880.78 mg·kg^{-1} treatments at day 30, showing certain epithelial hyperchromatism (asterisk). H&E (A, C) and H&VOF (B) staining. Scale bar: 50 μm

exposed the oligochaete *Lumbriculus variegates*, and the nemathode *Caenorhabditis elegans*, to LAS spiked sediments and derived NOEC values of 81 and 100 mg·kg^{-1}. However, the observed mortality occurred principally during the first 6 days of the experiment, which may also be related to transfer stress, and also, in higher exposure concentrations, stress due to swimming behaviour for the avoidance of the spiked sediment, which implies the mobilisation of energy resources which could be required for detoxification mechanisms. The reduction of energy available for detoxification finally results in higher mortality. Figure 1 shows the

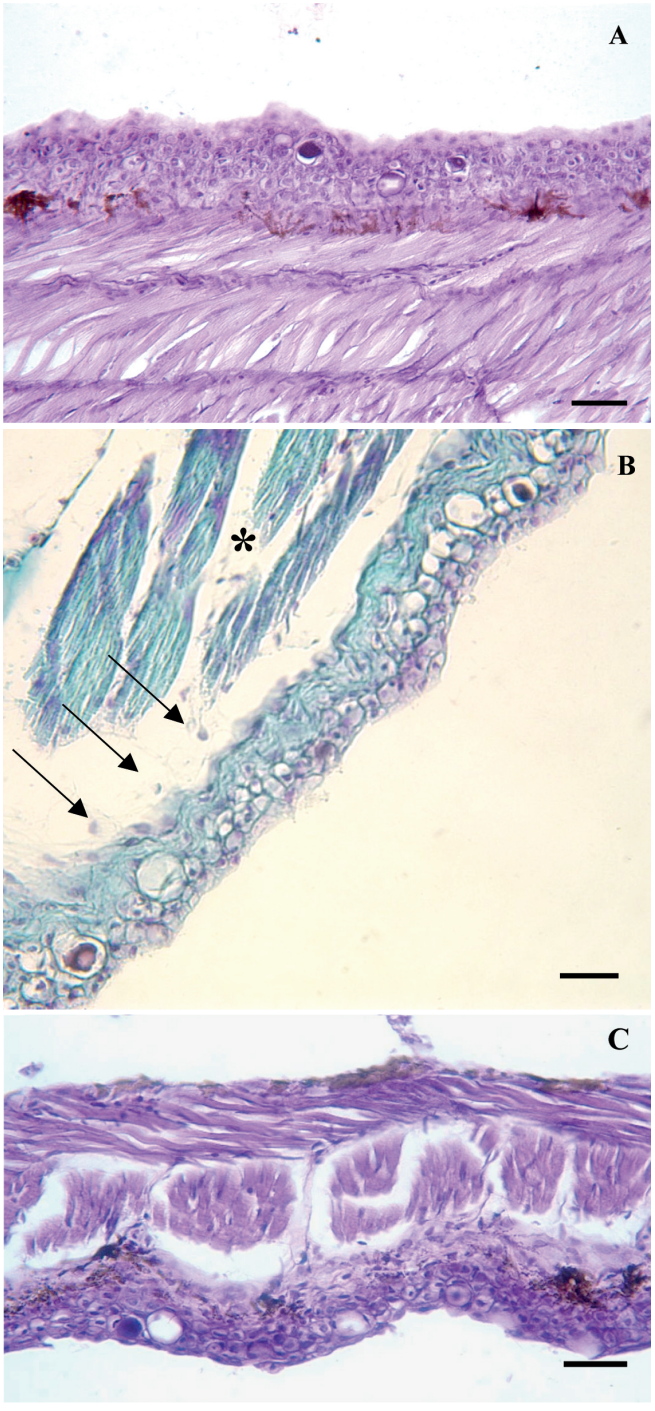

Fig. 9. Section of skin from control *S. senegalensis* showing normal distribution of the epidermis and dermis **(A)**. Sublethal effects in the epidermis of organisms from **(B)** 222.65 and **(C)** 880.78 mg·kg^{-1} treatments at day 30. Oedematous separations of the skin from the epidermis (arrows) as well as increasing of the inter-myotomal spaces from the musculature (asterisk) could be detected. H&E (A, C) and H&VOF (B) staining. Scale bar: 50 μm

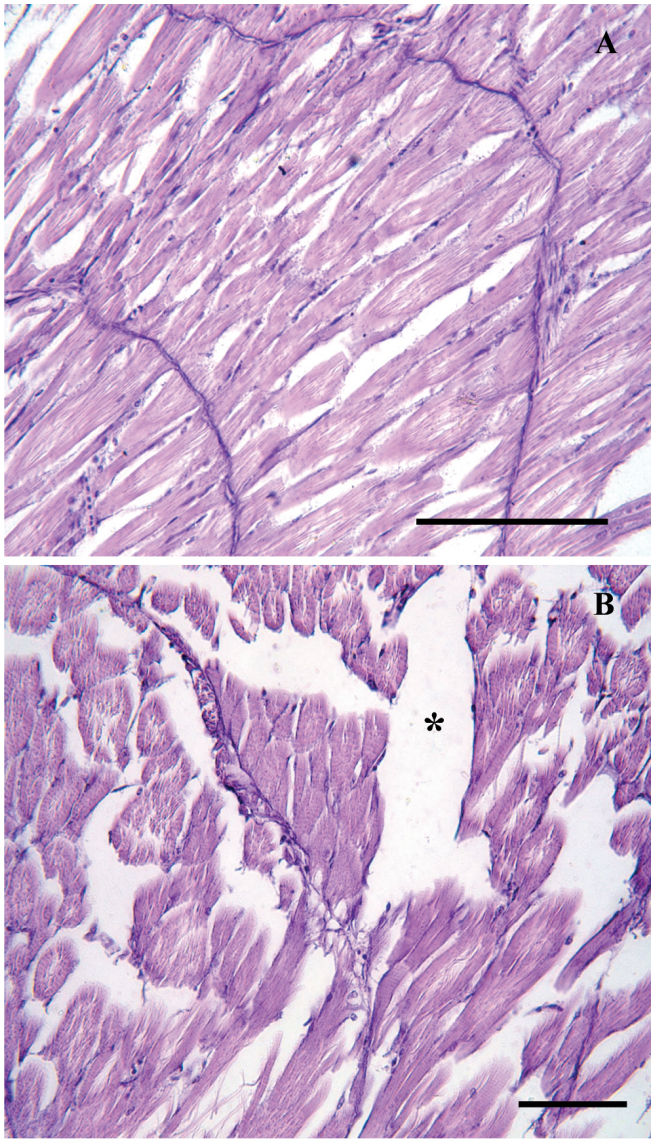

Fig. 10. Sections of the trunk musculature from **(A)** control and **(B)** 880.78 mg·kg^{-1} exposed organisms at day 30 of exposure, showing severe shrinkage of the myomers with increase of the inter-myotomal spaces (asterisk). H&E staining. Scale bar: 50 μm

mortality-time curve obtained in our assays at the two highest exposure concentrations. During the first days, an intense increase of mortality percentages is observed, whereas during the rest of the time, mortality remained constant. Handling of the larvae and their transfer into the experimental devices represented certain difficulties and submitted the organisms to considerable stress. It is possible that this stress debilitated the organisms, which in combination with the exposure to the surfactant may have increased their vulnerability, and therefore their mortality during the first days.

The LC_{50} value obtained in our experiments is 876.46 $mg \cdot kg^{-1}$ and surpasses environmental LAS levels reported in estuarine and coastal sediments (Takada and Ishiwatari, 1991; Takada et al., 1992a,b; González-Mazo et al., 1997, 1998; Lillebaelt Report, 1998; Marcomini et al., 2000) by two or three orders of magnitude. The PNEC (Predicted No Effect Concentration) value for LAS in marine sediments derived by the Human Environmental Risk Assessment for LAS (HERA-LAS, 2004) is 8.1 mg $LAS \cdot kg^{-1}$. This value is in good agreement with 8.81 mg $LAS \cdot kg^{-1}$ dry weight that could be derived from our results dividing the obtained LC_{50} value by 100 as proposed in the guidelines of the European Union (EU-TGD, 2003) for the derivation of PNEC (Predicted No Effect Concentration) by the application of assessment factors on acute or chronic toxicity data. Environmental LAS concentrations in marine sediments may reach in particular cases levels similar to these PNECs, but in those cases where adequate waste water treatment is guaranteed, LAS usually does not represent a hazard to the selected species.

Interestingly, histopatological alterations are frequently used as indicators of effect and exposure to anthropogenic contaminants in fish (Mondon et al., 2001). Gills of fish are critical organs for the respiratory and osmorregulatory functions, and histopathological changes in this organ, due to environmental stressors, have been reported by several authors (Mallat, 1985; Richmonds and Dutta, 1989; Arellano et al., 2001; Ortiz and Sarasquete, 2004; between others). Cellular and histopathological disorders in gills may contribute to problems related to respiration and acid-base balances (Leino et al., 1987).

Histological characteristics of the *Solea senegalensis* control organisms presented normal features of different organs and tissues (liver, pancreas, digestive tract, gills, etc), such as described previously (Ribeiro et al., 1999; Sarasquete et al., 2001). Hyperplasia with lamellar fusion and blood extravasation were the first histopathological disorders in gills of *S. senegalensis* at LAS concentrations of 222.66 $mg \cdot kg^{-1}$. Lamellar fusion may be a protective mechanism by diminishing the amount of vulnerable gill surface area (Mallatt, 1985; Ortiz et al., 2003). Blood extravasation and stagnation are signs of respiration failure. Since oxygen deficiency and an increase in red blood cell number in fish exposed to LAS were observed by Tomiyama (1974), he postulated that the inhibition of respiration was caused by an initial formation of a complex of LAS with a protein component in the gills that led to a loss of gill function. At the present time, a conclusion has not yet been obtained regarding the mode of action of LAS in acute toxic and chronic effects on fish, but it seems clear that gills are affected in some way. As gills provide the most extensive interface with the aquatic environment, it is to be expected that branchial structural changes are present in contaminated fish. In this sense, a high prevalence of hyperplasia in chloride and epithelial cells and lamellar fusion in gills were also detected in the greenback flounder *Rhombosolea tapirina* exposed to several contaminated sediments (Mondon et al., 2001).

The liver is a potential target organ for toxicants due to its large blood supply and great metabolic capacity (Hinton et al., 2001). Alterations in the liver may be useful biomarkers of effects that indicate exposure to environmental stressors. Approximately 85% of teleost liver volume is occupied by hepatocytes, the most numerous cell type. Stressor-associated alterations of hepatocytes may be found in the nucleus, in the cytoplasm, or both. Shrinkage of the hepatocytes and nuclear pycnosis are frequently detected in *S. senegalensis* specimens exposed to medium and highest LAS concentrations. Signs of atrophy and increased cytoplasm basophilia were detected in liver from *S. senegalensis* exposed to the highest LAS concentration. Changes in staining properties of cytoplasm are clear signals of toxicant exposure (Ortiz el at., 2003). The loss of cytoplasmic basophilia may be associated with ribosomal shearing from endoplasmic reticulum and swollen cisternae of the latter. The apparent increase of cytoplasmic basophilia is an early toxic response caused by a loss of hepatic glycogen (Sarasquete and Gutiérrez, 2005).

The kidney of fish receives much of the largest proportion of postbranchial blood, and therefore renal lesions might be expected to be good indicators of environmental pollution. Kendall (1975) found tubular degeneration and eosinophilic, proteinaceous intratubular casts and hyaline droplets, and an increase in the amount of hemosiderin or melanin-like intratubular deposits in catfish exposed to methyl mercury. In medaka specimens exposed to lindane isomers, Western and Canton (1986) found prominent glomerular hyalinosis as an indicator of renal toxicity. In *Mugil auratus* exposed to organic and inorganic mercury, Establier et al. (1978) observed renal epithelial necrosis, sloughing of the epithelium and accumulation of necrotic debris within the lumen of renal tubules. Loss of the interstitial haematopoietic tissue and epithelial hyperplasia with luminal occlusion of renal tubules was detected in kidney from exposed specimens of *S. senegalensis*. Similar alterations were detected in kidney of seabream *Sparus aurata*, following waterborne exposure to benzo(a)pyrene (B(a)P) (Ortiz-Delgado and Sarasquete 2004).

In the intestine, homogeneously distributed lipid

vacuoles are commonly observed in the cytoplasm of the intestinal enterocytes of *S. senegalensis* at highest LAS exposure. These clear vesicles of lipid origin, originally described as "steatosis" by Baglio and Farber (1965), might be the morphological expression of a blockage in the metabolism of triglycerides due to a defective synthesis of very low density lipoproteins (Braunbeck et al., 1990). Although the precise mechanism by which tissue injury occurs is unclear, the histopathological alterations resulting from LAS exposure may lead to a reduction in the functional efficiency of the affected organs, leading to malfunctioning of several organ systems of the fish. In our study, alterations in intestine have only been found at the highest LAS concentrations.

The increasing difference between wet and dry weight at the end of the experiment may be analysed in combination with the results obtained in the histopathological analysis of trunk musculature and the epidermis. In preparations from highest exposure concentrations, a retraction of the myomers of the musculature was frequently observed, increasing the inter-myotomal spaces, as well as an edematous separation of the epidermis, respectively. Myomers are laminar muscle structures connected by thin collagen layers. This collagen connecting tissue could be affected by the presence of the surfactant and lose its connecting property. Combined with the edematous separation of the epidermis from the underlying tissue it may result in the pronounced increase in wet weight in comparison with the dry weight at the end of the experiment. Simultaneously, it was observed that organisms from highest exposure concentration presented greater sizes than those from the control experiment in general (unpublished data). Misra et al. (1987) detected a pronounced increase in mucus production in specimens of *Cirrhia mrigala* exposed to 0.005 ppm LAS, and alterations in this tissue have been proposed as a sublethal effect indicator of contamination, as the skin is the most directly exposed organ to any kind of environmental pollution. On the other hand, skin can also be a target organ in aqueous exposures of larval fish utilizing skin respiration during development (Sarasquete et al., 2001). In bottom-dwelling species, the skin may even have direct contact with contaminated sediments and their pore waters (McKim and Lien, 2001).

The first histological changes in *S. senegalensis* were observed in our tests with sediment sorbed LAS at concentrations of 222.66 $mg \cdot kg^{-1}$, which is several orders of magnitude higher than in aqueous phase. Even though larvae are known to be much more sensitive towards contaminant exposure (Korn and Rice, 1981; McKim, 1985), in neonate (<24h) larvae of the seabream, *Sparus aurata*, the first signs of histological changes after exposure to dissolved LAS were observed at a concentration of 0.2 $mg \cdot L^{-1}$ and higher exposure concentrations (1.0 $mg \cdot L^{-1}$) provoked disorganisation of the nervous system, trunk musculature and trophoblastic syncytium, as well as in the digestive epithelium (Hampel et al., 2004). These results indicate that once sorbed onto suspended matter and particles, sediments may act as effective sink for LAS.

Acknowledgements. This work has been supported by the research contract CSIC-PETRESA "Effects of Linear Alkylbenzene Sulfonate on benthic organisms" founded by PETRESA. We thank PETRESA for the LAS supply and the fellowship of M. Hampel, as well as Mr. P. Lara, Ms. M. Saéz and Ms. D. Álvarez for their valuable help with the LAS analysis.

References

Arellano J.M., Ortiz J.B., Gonzalez de Canales M.L. and Sarasquete C. (2001). Histopathological alterations and induction of cytochrome P-450 1A in the liver and gills of the gilthead seabream (*Sparus aurata*) exposed to 2,3,7,8-tetrachlorodibenzo-p-dioxin. Histochem. J. 33, 663-74.

Arellano J.M. and Sarasquete C. (2005). Atlas Histológico del lenguado senegalés *Solea senegalensis* (Kaup, 1858). Servicio de Publicaciones del CSIC. Spain.

Baglio C.M. and Farber E. (1965). Reversal by adenine of the ethiline-induced lipid accumulation in the endoplasmic reticulum of the rat liver. J. Cell Biol. 27, 591-601.

Braunbeck T., Görge G., Strorch V. and Nagel R. (1990). Hepatic steatosis in zebrafish (*Brachydario rerio*) induced by long term exposure to hexachlorocyclohexane. Ecotox. Environ. Safety 24, 72-94.

Bucke D., Vethaak D., Lang T. and Mellergaard S. (1996). Common diseases and parasites of fish in the North Atlantic: training guide for identification. International council for the exploration of the sea. Techniques in marine environmental sciences. Copenhagen.

Cabral H.N. (2000). Comparative feeding ecology of sympatric *Solea solea* and *S. senegalensis*, within the nursery areas of the Tagus estuary, Portugal. J. Fish Biol. 57, 1550-1562.

Casellato S., Aiello R., Negrisolo P.A. and Seno M. (1992). Long-term experiment on *Branchiura sowerbyi* Beddard (Oligochaeta, Tubificidae) using sediment treated with LAS (Linear Alkylbenzene Sulphonate). Hydrobiologia 232, 169-173.

Collier T.K., Johnson L.L., Myers M.S., Stehr C.M., Krahn M.M., Stein J.E. (1998). Fish injury in the hyleboss waterway of commencement bay. Washington. U.S. Dept. Commer., NOAA Tech. Memo. NMFS-NWFSC-36.

Comber S.D.W., Conrad A.U., Höss S., Webb S. and Marshall S. (2006). Chronic toxicity of sediment-associated linear alkylbenzene sulphonates (LAS) to freshwater benthic organisms. Env. Poll. 144, 611-668.

Dinis M.T., Ribeiro L., Soares F. and Sarasquete C. (1999). A review on the cultivation potential of *Solea senegalensis* in Spain and in Portugal. Aquaculture 176, 27-38.

Duft M., Schulte-Oehlmann U., Weltje L., Tillmann M., Oehlmann J. (2003). Stimulated embryo production as a parameter of estrogenic exposure via sediments in the freshwater mudsnail *Potamopyrgus antipodarum*. Aquatic Tox. 64, 437-449.

Establier R., Gutiérrez M. and Arias A. (1978). Acumulación y efectos histopatológicos del mercurio inorgánico y orgánico en la lisa (*Mugil auratus* Riso). Inv. Pesq. 42, 65-80.

European Union. (2003). Technical Guidance Document on Risk

Assessment in support of the Commission Directive 93/67/EEC on Risk Assessment for new notified substances Commission Regulation (EC) No 1488/94 on Risk Assessment for existing substances Directive 98/8/EC of the European Parliament and of the Council concerning the placing of biocidal products on the market. Environmental Chemicals Bureau, Ispra, Italy.

González-Mazo E., Forja J.M. and Gómez-Parra A. (1998). Fate and distribution of linear alkylbenzene sulfonates in the litoral environment. Environ. Sci. Technol. 32, 1636-1641.

González-Mazo E., Honing M., Barceló D. and Gómez-Parra A. (1997). Monitoring long-chain intermediate products from the degradation o0f linear alkylbenzene sulfonates in the marine environment by solid-phase extraction followed by liquid chromatography/isospray mass spectometry. Environ. Sci. Technol. 31, 504-510.

Gutiérrez M. (1990). Nuevos colorantes biológicos y citohistoquímica de la coloración. PhD Thesis. Facultad de Químicas, Universidad de Cádiz, Cádiz, Spain.

Hampel M., Ortiz-Delgado J.B., Moreno-Garrido I., Sarasquete C. and Blasco J. (2004). Sublethal effects of linear alkylbenzene sulphonate on larvae of the seabream (*Sparus aurata*): histological approach. Histol. Histopathol. 19, 1061-1073.

Hand V.C. and Williams G.K. (1987) Structure-Activity relationships for sorption of linear alkylbenzene sulphonates. Environ. Sci. Technol. 21, 370-373.

HERA-LAS. Human and Environmental Risk Assessment LAS CAS No 68411-30-3. Version No. 9. (2004). (http://www.heraproject.com/Index.cfm). A.I.S.E. Association Internationale de la Savonnerie, de la Détergence et des Produits d'Entretien (www.aise-net.org), Cefic. European Chemical Industry Council (www.cefic.org).

Hinton D.E., Segner H. and Braunbeck T. (2001). Toxic responses of the liver. In: Target organ toxicity in marine and freshwater teleosts. Vol. 1: Organs. Schlenk D. and Benson W.H. (eds). Taylor and Francis, London. pp. 224–268.

Ingersoll C. and Nelson M.K. (1990). Testing sediment toxicity with *Hyalella azteca* (Amphipoda) and *Chironomus riparius* (Diptera). In: Aquatic toxicology and risk assessment. Thirteenth Volume STP 1096. Landis W.G. and Van der Schalie W.H. (eds). American Society of Testing and Materials. Philadelphia. pp 93-109.

Kendall M.W. (1975). Acute effect of methyl mercury toxicity in channel catfish kidney. Bull. Environ. Contam. Toxicol. 13, 570-575.

Kerr D.R. and Meador J.P. (1996). Modelling dose-response using generalized linear models. Environ. Tox. Chem. 15, 395-401.

Korn S. and Rice S. (1981). Sensitivity to, and accumulation and depuration of, aromatic petroleum components by earth life stages of coho salmon (*Onchorhynchus kisutch*). Rapp. P. V. Reun. Explor. Mer.

Leino R.L., Wilkinson P. and Anderson J.G. (1987). Histopathological changes in the gills of pearl dace, *Semotilus margarita* and fathead minnows, *Pimephales promelas*, from experimentally acidified Canadian lakes. Can. J. Fish Aquat. Sci. 44, 126-134.

León V.M., González-Mazo E. and Gómez-Parra A. (2000). Handling of marine and estuarine samples for the determination of linear alkylbenzene sulfonates and sulfophenylcarboxylic acids. J. Chrom. A. 889, 211-219.

Lillebaelt Report (1998). The Lillebaelt Cooperation. Denmark, December 1998.

Malins D.C., Krahn M.M., Brown D.W., Rhodes L.D., Meyers M.S., McCain B.B. and Chan S.L. (1985). Toxic chemicals in marine sediment and biota from Mukilteo, Washington: relationships with hepatic neoplasms and other hepatic lesions in English sole (*Parophrys vetulus*). J. Natl. Cancer Inst. 74, 487-494.

Mallat J. (1985). Fish gill structural changes induced by toxicants and other irritants: A statistical review. Can. J. Fish. Aquat. Sci. 42, 630-648.

Matthiessen P., Allen Y.T., Allchin C.R., Feist S.W., Kirby M.F., Law R.J., Scott A.P., Thain J.E. and Thomas K.V. (1998). Estrogenic endocrine disruption in flounder (*Platichthys flesus* L.) from United Kingdom estuarine and marine waters. Sci. Ser., Tech. Rep., CEFAS, Lowestoft, (107).

Matthijs E. and De Henau H. (1985) Adsorption and Desorption of LAS. Tenside Detergents 22, 299-304.

Marcomini A., Pojana G., Sfriso A. and Quiroga-Alonso J.M. (2000). Behaviour of anionic and nonionic surfactants and their persistent metabolites in the Venice Lagoon, Italy. Environ Toxicol. Chem. 19, 2000-2007.

Marin M.G., Pivotti L., Campesan G., Turchetto M. and Tallandini L. (1994). Effects and fate of sediment sorbed linear alkylbenzene sulphonates (LAS) on the bivalve mollusc *Mytilus galloprovincialis*. Wat. Res. 28, 85-90.

McKim (1985). Early life stage toxicity tests. In: Fundamentals of aquatic toxicology. Rand G.M. and Petrocelli S.R. (eds). Hemisphere publishing Corporation, Washington D.C. pp 58-95.

Misra V., Chawla G., Kumar V., Lal H. and Viswanathan P.N. (1987) Effect of linear alkyl benzene sulfonate in skin of fish fingerlings (*Cirrhina mrigala*): Observations with scanning electron microscope. Ecotox. Env. Safety 13, 164-168.

Mondon J.A., Duda S. and Nowak B.F. (2001). Histological growth and 7-ethoxyresorufin O-deethylase (EROD) activity responses of greenback flounder *Rhombosolea tapirina* to contaminated marine sediment and diet. Aquatic Tox. 54, 231-247.

Myers M.S., Johnson L.L., Olson O.P., Stehr C.M., Horness B.H., Collier Y.K. and McCain B.B. (1998). Toxicopathic hepatic lesions as biomarkers of chemical contaminant exposure and effects in marine bottom fish species from the Northeast and Pacific Coast, USA. Mar. Pollut. Bull. 37, 92-113.

Myers M.S., Landahl J.T., Krahn M.M., Johnson L.L. and McCain B.B. (1990). Overview of studies on liver carcinogenesis in English sole from Puget Sound; evidence for a xenobiotic chemical etiology I: pathology and epizootiology. Sci. Total Environ. 94, 33-50.

Ortiz J.B., González de Canales M.L. and Sarasquete C. (2003). Histopathological changes induced by lindane in various organs of fishes. Sci. Mar. 67, 53-61.

Ortiz-Delgado J.B. and Sarasquete C. (2004). Toxicity, histopathological alterations and immunohistochemical CYP1A induction in the early life stages of the seabream, *Sparus aurata*, following waterborne exposure to B(a)P and TCDD. J. Molec. Hist. 35, 29-45.

Ortiz-Delgado J.B., Ruane N.M., Pousão-Ferreira P., Dinis M.T. and Sarasquete C. (2006). Thyroid gland development in Senegales sole, *Solea senegalensis* Kaup 1858) during early life stages: a histochemical and immunohistochemical approach. Aquaculture (in press)

Piñuela C., Rendón C., Gonzalez De Canales M.L. and Sarasquete C. (2004). Development of the CNS, Specially the forebrain of the sole, *Solea senegalensis*. Eur. J. Histochem. 48, 377-384.

Ribeiro L., Sarasquete C. and Dinis M.T. (1999). Histological and histochemical characteristics during development of the Senegal

sole, *Solea senegalensis*. Aquaculture 171, 291-306.

Richmonds C. and Dutta M.H. (1989). Histopathological changes induced by malathion in the gills of bluegill *Lepomis macrochirus*. Bull. Environ. Contam. Toxicol. 43, 123-130.

Sarasquete C., Gonzalez De Canales M.L., Arellano J.M., Muñoz-Cueto J.A., Ribeiro L. and Dinis M.T. (1996). Histochemical aspects of the yolk-sac and digestive tract of the Senegal sole, *Solea senegalensis*. Histol. Histopathol. 11, 881-888.

Sarasquete C., Gonzalez De Canales M.L., Arellano J.M., Muñoz-Cueto J.A., Ribeiro L. and Dinis M.T. (1998). Histochemical study of skin and gills of Senegal sole, *Solea senegalensis* larvae and adults. Histol. Histopathol. 13, 727-735.

Sarasquete C., Gisbert E., Ribeiro L., Vieira L. and Dinis M.T. (2001). Glycoconjugates in epidermal, branchial and digestive mucous cells and gastric glands of gilthead seabream, *Sparus aurata*, Senegal sole, *Solea senegalensis* and Siberian sturgeon, *Acipenser baeri*. Eur. J. Histochem. 45, 267-278.

Sarasquete C. and Gutiérrez M. (2005). New tetrachromic VOF stain (Type III-G.S) for normal and pathological fish tissues. Eur. J. Histochem. 49, 105-114.

Sindermann C.J. (1979). Pollution-associated diseases of fish and shellfish: a review. Fish. Bull. 76, 717-749.

SETAC (1993). Guidance document on sediment toxicity tests and bioassays for freshwater and marine environments. From the "Workshop on Sediment Toxicity Assessment", Renesse, The Netherlands.

Takada H. and Ishiwatari R. (1991). LABS in urban riverine environments in Tokyo: distribution, source and behaviour. Environ. Sci. Technol. 21, 875-883.

Takada H., Ogura N. and Ishiwatari R. (1992a). Sesonal variations and modes of riverine input of organic pollutants to Tokyo Bay. Environ. Sci. Technol. 26, 2517-2523.

Takada H., Ishiwatari R. and Ogura N. (1992b). Distribution of Lineal Alkylbenzenes (LABs) and Linear Alkylbenzenesulphonates (LAS) in Tokyo Bay sediments. Estuar. Coastal Shelf Sci. 35, 141-156.

Tomiyama S. (1974). Effects of surfactants on fish Bull. Jap. Soc. Sci. Fish.

Urano K., Saito M. and Murata C. (1984). Adsorption of surfactants on sediments. Chemosphere 13, 293-300.

US EPA. (1994). Methods for measuring the toxicity and bioaccumulation of sediment-associated contaminants with fresh water invertebrates. EPA/600/R-94/024. US Environmental Protection Agency, Office of Research and Development, Washington, DC.

Vethaak A.D., Bucke D., Lang T., Wester P.W., Jol J. and Carr M. (1992). Fish disease monitoring along a pollution transect: a case study using dab (*Limanda limanda*) in the German Bight. Mar. Ecol. Prog. Ser. 91, 173-192.

Vethaak A.D., Rijs G.B.J., Schrap S.M., Ruiter H., Gerritsen A. and Lahr J. (2002). Estrogens and xeno-estrogens in the aquatic environment in the Netherlands. Occurrence, potency and biological effects. RIKZ/RIZA report no. 2002.001.

Western P.W. and Canton J.H. (1986). Histopathological study of *Oryzias latipes* after long term hexachlorociclohexane exposure. Aquat. Toxicol. 9, 21-45.

Wheeler J.R., Grist E.P.M., Leung K.M.Y., Morritt D. and Crane M. (2002). Species sensitivity distributions: data and model choice. Mar. Poll. Bull. 45, 192-202.

Accepted July 16, 2007