

Mandibular bone alterations of ovariectomized rats under vitamin D insufficiency

Faika Said^{1,2*}, Sonia Ghoul-Mazgar¹, Blandine Ruhin^{3,4}, Mohieddine Abdellaoui⁵,
Faycel Chlaghmia¹, Sihem Safta¹, Leila Guezguez⁶, Dalila Saidane-Mosbahi² and Fathia Khemiss^{2,7*}

¹Laboratory of Histology and Embryology, Faculty of Dental Medicine, Tunisia, ²Laboratory of analysis, treatment and Valorisation of Environmental Pollutants and Products, Faculty of Pharmacy, Tunisia, ³Laboratory of Orofacial Biology and Pathology – Centre de recherche des Cordeliers, Paris, France, ⁴Stomatology and Maxillofacial Surgery Department, Pitié Salpêtrière Hospital Paris VI University, France, ⁵Laboratory of Physic chemistry and Engineering of Materials, National Institute of Research and Physic Chemistry Analysis, Technological Park, Tunisia ⁶Department of Periodontology, Faculty of Dental Medicine, Monastir, Tunisia and ⁷Laboratory of Physiology, Faculty of Dental Medicine, Monastir, Tunisia

*Both contributed equally to this work.

Summary. Experimental osteoporosis was studied in mandible bone by means of ovariectomy and vitamin D insufficiency. **METHODS:** 42 female Wistar rats were divided into the following four groups: (1) ovariectomized rats maintained in 12h day-night light conditions (ov-l), (2) ovariectomized rats maintained in 24h dark light conditions (ov-ob), (3) sham-operated rats maintained in 12h day-night light conditions (ch-l) and (4) sham-operated rats maintained in 24 h dark conditions (ch-ob). 12 weeks later the animals were sacrificed, the mandibles were excised, cleaned and weighed, the right side of the mandibles were histologically examined and the left side of the mandibles were prepared for mineral phase analysis by X-ray diffraction. Immunohistochemical analysis was performed to detect apoptotic cells by anti-PARP p85 antibody. **RESULTS:** In group 2, the weight of mandibles significantly decreased. Chondroid areas were observed in ovariectomized groups and polarized light observation validated the collagen distribution disturbance in these groups (groups 1 and 2). Apoptotic osteoblasts were localized in groups 1, 2 and 4. They were numerous in group 2. The mineral phase analysis did not find differences between the groups. **CONCLUSION:** This study validates a new model of osteoporotic animal associating estrogens deficiency and vitamin D insufficiency where matrix synthesis and osteoblast biology are altered, but not biomineralization.

Key words: Ovariectomy, Vitamin D insufficiency, Mandible

Introduction

Osteoporosis is characterized by microarchitectural deteriorations resulting in bone fragility.

Osteoporosis does not only affect long bones but also osseous tissues of the oral cavity such as the mandible (Moriya et al., 1998; Tanaka et al., 2002; Ikeo et al., 2007). Although numerous studies have documented the possible role of osteoporosis in mandibular bone resorption (Bianchi and Sanfilippo, 2002), changes in the mandible during the development of osteoporosis have not been studied extensively. The effect of osteoporosis on mandibular bone structure has not been well-defined because of the difficulties inherent to studying human bone loss in mandible. Oral osteoporosis, and the underlying loss of bone mass that is a characteristic of this disease, is associated with periodontal disease, tooth loss and other oral tissue changes (Dervis, 2005). However, clinical information concerning the association between osteoporosis and oral bone status remains a matter of controversy. Even if individuals with osteoporosis may develop oral osteoporosis, such a risk is not definitively proven (Dervis, 2005) and the systemic loss of oral bone density in osteoporosis is likely to be overstated by infections of periodontal origin (Wactawski-Wende, 2001; Lerner, 2006). Further, well-controlled studies are needed to better elucidate the inter-relationship between osteoporosis and oral bone loss.

Several factors, such as estrogen deficiency or

vitamin D insufficiency may induce osteoporosis (Carlsten, 2005; Raisz, 2005). Estrogen deficiency is one of the most important factors in the pathogenesis of osteoporosis. In fact, this hormone plays a fundamental role in skeletal growth and homeostasis. Osteoporotic changes due to estrogenic deficiency have been associated with an imbalance between bone formation and bone resorption (Weitzmann and Pacifici, 2006). On the other hand, while vitamin D insufficiency leads to secondary hyperparathyroidism and to increased bone resorption, resulting in osteoporosis, severe vitamin D deficiency causes impaired bone mineralization (osteomalacia). Nutritional sources of vitamin D are limited and the major source is from sun exposure (Epstein, 2006; Lips, 2006).

The aim of this study was to examine the combined osteoporotic effects of both estrogen deficiency and vitamin D insufficiency on (i) mandible bone structure, (ii) bone cell activity and (iii) mineralization. The ovariectomized rats used in this study have been widely used as a model of osteoporosis (Wronski et al., 1985; Kalu, 1991) and it is an excellent model to investigate the effects of estrogen deficiency on bone. The experimental model associating ovariectomy to vitamin D insufficiency would be very useful to study the relationship between bone loss and insufficient status of vitamin D (Correa et al., 1992; Mastaglia et al., 2006).

Materials and methods

Animals and experimental protocol

Forty two female Wistar rats, 12-week-old (134.75-161.25g) were used. During the experimental period, the animals were permitted free access to laboratory conventional food and water. All rats were housed in a cage with 60% humidity at 21°C. After one week of acclimatization period, 25 rats were assigned to undergo bilateral ovariectomy and 17 rats were subjected to a sham operation in accordance with previously established techniques (Wronski et al., 1985). To induce vitamin D deficiency, rats were kept in complete darkness according to a previous study (Correa et al., 1992). Rats were randomly divided into four groups: 1)- ovariectomized rats exposed to 12h day-night light conditions (ov-l); 2)- ovariectomized rats maintained in 24h dark conditions (ov-ob); 3)- sham-operated rats maintained in 24h dark conditions (ch-ob); and 4)- sham-operated rats exposed to 12h day-night light conditions (ch-l).

The weights of all the rats are noted at the beginning of the study, at the 9th week and at 12th week of procedure. All rats were killed by cervical dislocation after 12 weeks. The mandible of each rat was dissected, cleaned and weighed.

Histological analysis

The right side of the divided mandible bones were

fixed in 10% formaldehyde for about 48h and demineralised in 10% EDTA (Ethylenediamine tetracetique) (pH 7) for about 25 days. Demineralised tissues were embedded in paraffin and cut longitudinally into 8µm-thick sections by a Reichert-Jung G 2030 microtome. The sections were stained with haematoxylin-eosin, and examined under a binocular light microscope (Axioskop - Zeiss).

Immunohistochemical analysis

Sections were deparaffinized, rehydrated and treated with citrate buffer (10 mM, pH 6) in the Microwave. Sections were washed with 0.1 M phosphate-buffered saline (PBS) pH 7.3 and treated for 5 min with H₂O₂ in methanol, then incubated for 1 h with the primary antibody (rabbit anti-PARP p85 dilute in 1/100 in PBS). After rinsing, they were incubated for 30 min with alkaline phosphatase conjugated secondary antibodies (Amersham, France). The immune complexes were detected using the developing solution NBT-BCIP. Non-relevant rabbit immunoglobulins were used as negative control.

X ray diffraction

The left side of the divided mandibles were used to microdissect alveolar bone. Bone specimens were dehydrated and reduced to powder. A diffraction pattern was recorded from each sample of bone powder using a (θ-2θ) Panalytical X'Pert PRO MPD diffractometer, using Cu Kα₁ radiation (λ = 0.15406 nm). Bone powder for each group was deposited on a sample holder mounted on a sample spinner allowing the reduction of any effects of grain size distribution in the sample throughout the period of irradiation. The powder diffracts the X-rays in accordance with Bragg's law. High Score plus program was used in order to analyze the XRD patterns and to obtain the position, the intensity and the full width at half high of the various peaks.

Statistical analysis

Statistics were computed with the SPSS for Windows. Body weight and mandibular weight analyses are expressed as mean standard deviation (SD). Statistical differences between groups were evaluated by analysis of variance (ANOVA) for multiple comparisons. Simple comparisons between two means were made using the Student test. The differences observed were considered significant for p ≤ 0.05.

Results

Weight analysis (Figure 1 and Figure 2)

In the four groups there was a steady increase in body weight during the observation period (Fig. 1). Body weight mean in the group (ov-ob) is significantly

Mandible bone of ovariectomized rats under vitamin D insufficiency

higher than that of group (ch-l) at the end of the observation period. After a 12-week procedure, the comparative analysis of the weight of the cleaned mandibles among the groups (Fig. 2) seems to be significantly lower in the group (ov-ob). Vitamin D

insufficiency or estrogens deficiency considered alone failed to show significant difference of the mandible weight compared to the control group (Ch-l).

Bone turn-over (Figure 3)

The unbalanced bone turn-over was seen histologically in the periodontium of the different groups. The apoptotic osteoblasts were best detected immunohistochemically using the anti-PARP p85 antibody in the alveolar crest. While apoptotic

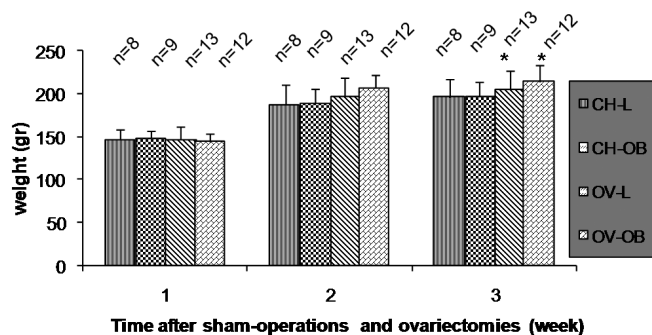


Fig. 1. Comparison of body weights in the four groups studied following 12-week procedure. Measurements were performed at the beginning of the procedure at 9 weeks and at 12 weeks. Values are mean \pm SD. Data analyzed by one-way ANOVA showed significant difference for all the groups between the different periods (1 and 2 $p \leq 0.001$; 1 and 3 $p \leq 0.01$; 2 and 3 $p \leq 0.01$). After a 12-week procedure, intergroup analysis showed significant difference between ovariectomized groups (ov-ob and ov-l) and sham-operated groups (ch-l and ch-ob) ($p \leq 0.05$).

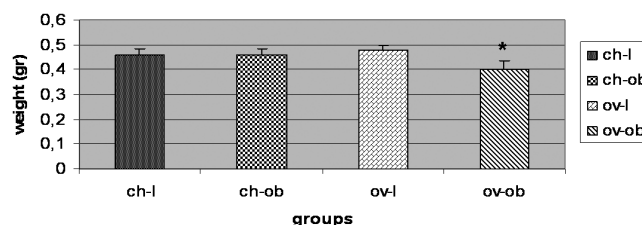


Fig. 2. Mandible weight variations after the experimental period. After 12 weeks of procedure, data analyzed by Student test showed that the mandible weight mean of the group (ov-ob) was significantly higher than the mandible weight mean of (ov-l), (ch-ob) and (ch-l) groups ($p < 0.001$). However, there was statistically no weight difference for the mandible weight between ov-l and ch-l groups or ch-ob and ch-l groups.

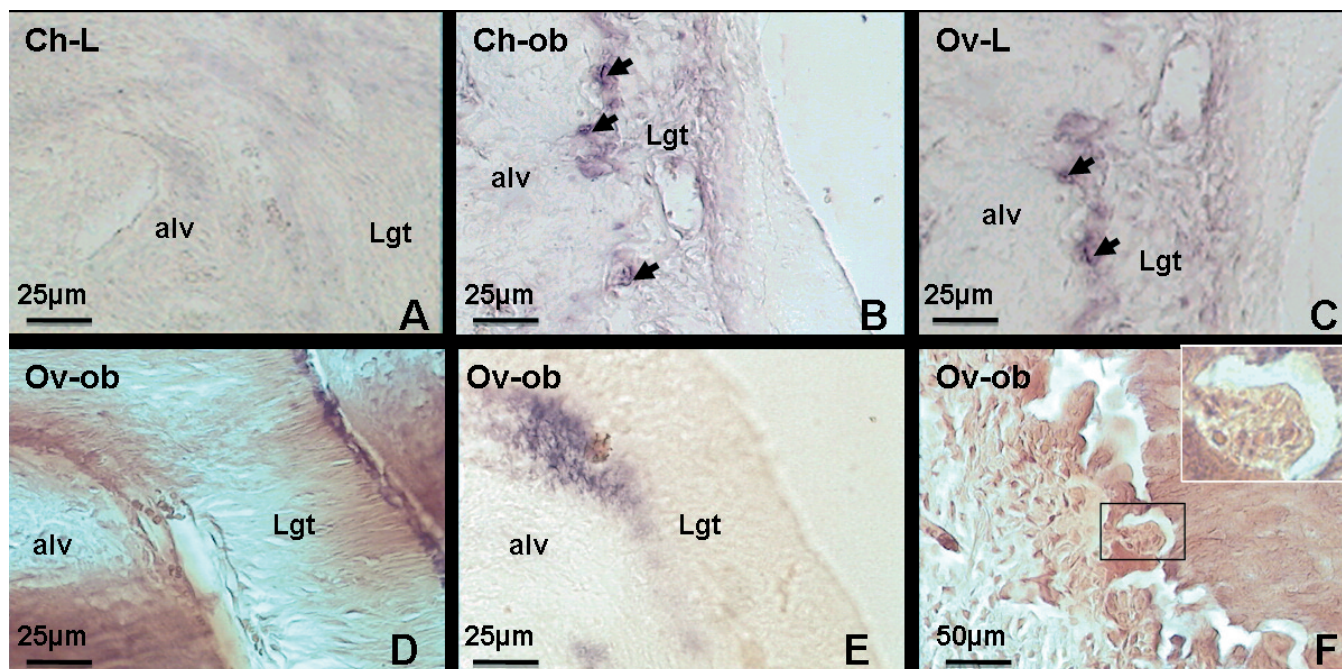


Fig. 3. Immunohistochemical detection of apoptotic cells among the groups. Positive immunohistochemical apoptotic cells have been detected for all the groups in the alveolar crest. Compared to group (Ch-l) which did not show apoptotic cells (A), few apoptotic osteoblastic cells were detected in the alveolar crest of groups (Ch-ob) (arrows in Figure B) and group (Ov-l) (arrows in Figure C). In group (ov-ob) analysis of the alveolar crest (D, HE) showed numerous apoptotic osteoblasts especially in the top of the crest (Figure E). In this group, osteoclasts are easily detected on the polycyclic surfaces of the bone-resorbing areas (Figure F, HE). HE: haematoxylin-eosin stain.

Mandible bone of ovariectomized rats under vitamin D insufficiency

osteoblasts were not seen in the control group (ch-l), they became detectable in groups (ch-ob) and (ov-l). This observation seems to be more evident in the group of ovariectomized rats maintained in dark conditions (ov-ob). In this group osteoclasts were easily identified adjacent to the polycyclic border of the cribriform surfaces.

Bone structure (Figure 4)

The examination of mandibles in decalcified sections under the light microscope revealed the presence of chondroid areas in the compact bone of ovariectomized rats (both groups ov-l and ov-ob). The examination of these sections under polarized light confirmed disturbance in the organisation of collagen fibres. Neither chondroid areas, nor a collagen disturbance were detected in sham operated groups.

Bone mineralization (Figure 5)

The superposition of the X-ray diffraction patterns

of the different studied groups revealed a comparable profile of the mineral phase of each group suggesting that the procedure did not affect the mineral phase of the mandible bones. In fact, the phase identification using the high score plus program software, based on the PDF2 database, showed that the studied material is mainly formed by the hydroxyapatite $\text{Ca}_{10}(\text{PO}_4)_6(\text{OH})_2$.

Discussion

The ovariectomized rat has been widely used as a model of postmenopausal osteoporosis (Wronski et al., 1985; Kalu, 1991). Due to an insufficient length of experimental follow-up, many studies have failed to detect any changes in mandibular bone following ovariectomy. Some authors have shown that the period of 12 weeks after surgery had no effect on bone loss in the mandible using this rat animal model (Hara et al., 2001). The low susceptibility of the mandible to bone loss may also be due to functional masticatory forces maintaining the bone mass (Kuroda et al., 2003).

On the other hand, it has been previously shown in

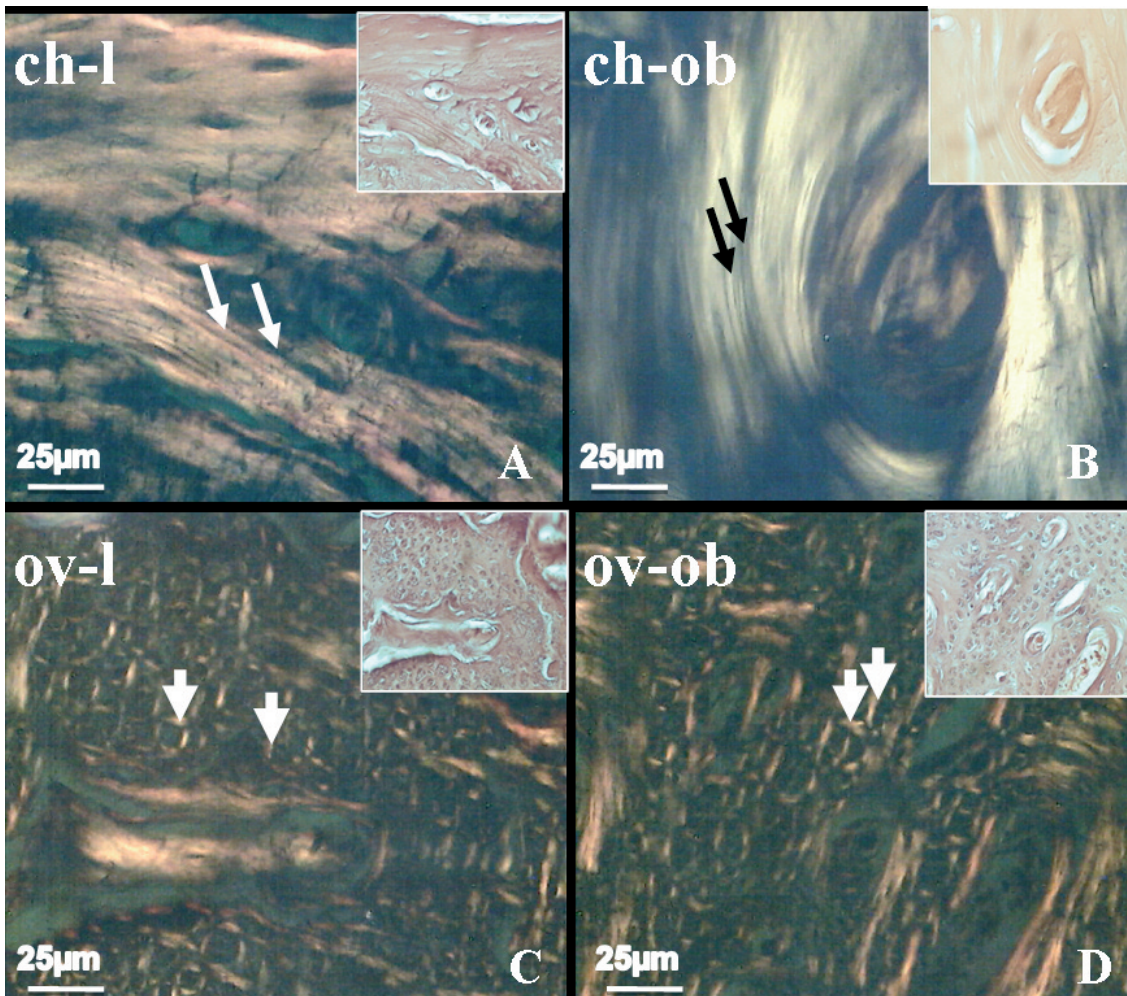


Fig. 4. Mandibular compact bone observed by polarized microscopy. Neither group (Ch-l) (A), nor group (Ch-ob) (B) showed disturbance in the mandibular structure explored in the light and in the polarized microscopes. Areas of chondritic aspect have been observed into the mandibular compact bone in group (Ov-l) (frame image in C, HE) and group (Ov-ob) (frame image in D, HE). Observation of the same areas under polarized microscopy revealed disturbance of the orientation of collagen fibres in these areas shown by the altered distribution of the clear and dark bands, in group (Ov-l) (arrows in Fig. C, HE) and group (Ov-ob) (arrows in D, HE). HE: Haematoxylin-eosin stain.

Mandible bone of ovariectomized rats under vitamin D insufficiency

humans that following a period of 3 months of complete darkness, there was a significant fall in 25-hydroxy vitamin D values (Fairney and Lipscomb, 1979). In another study, rats were kept in complete darkness during 15 days to promote experimental vitamin D insufficiency (Correa et al., 1992). In our study we associated ovariectomy to vitamin D deficiency for a follow-up of 12 weeks and we demonstrated the influence of the association of these two factors on bone structure.

As described in other studies (Namkung-Matthai et al., 2001; Lee et al., 2006; Lien et al., 2006; Tromp et al., 2006), there was an increase in the body weight in ovariectomized rats. In order to confirm mandibular osteoporosis process enhanced by the association of these two factors, mandible weights were firstly analysed (Fig. 2). There was a significant decrease of the mandible weight in the group of ovariectomized rats maintained in dark conditions (ov-ob). Each factor (estrogen deficiency or vitamin D insufficiency) taken alone, is unable to bring significant mandible weight decrease. These data suggested testing the value of our model in evaluating bone structure, bone cell activity and bone mineralization under the association of these two osteoporotic factors.

Afterwards, although histological features of mandibular bone were noted in our study following 12 weeks of treatment, other studies (Shirai et al., 2002) have histomorphometrically demonstrated that the mandible bone alterations of ovariectomized rats are seen even after only 60 days following ovariectomy (Tanaka et al., 2002).

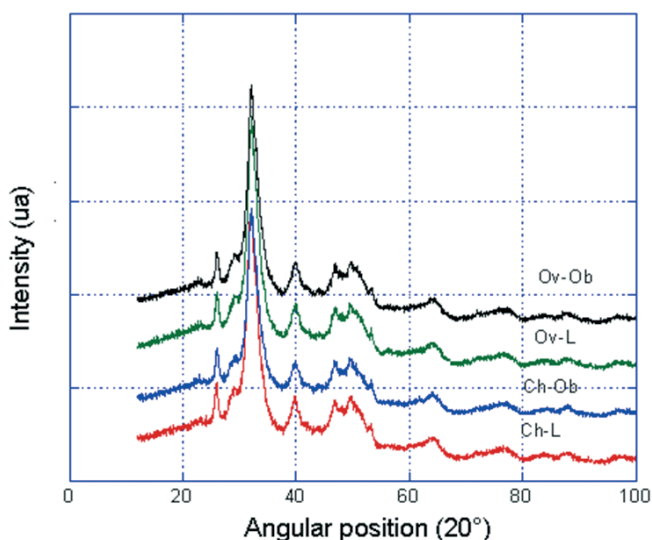


Fig. 5. Comparison of the mineral phase XRD patterns of the bone mandible between the four groups. X-ray diffraction was used to explore the crystalline system of hydroxyapatite (HAP) between the four groups. Unit cell dimensions and crystallite size were measured from $2\theta=25^\circ$ to 50° under no deformation revealed no differences in the XRD pattern profile of mandible bone between the four groups.

Interestingly, our study established the presence of chondroid aspects in the mandibular bone of the ovariectomized groups that were associated with a disturbed distribution of the collagen fibres. An alteration of the composition of the matrix in ovariectomized rats has been previously described (Cesnjaj et al., 1991; Li and Nishimura, 1994). Moreover, the combined osteoporotic effect of two variables on fracture callus of rat's femur has revealed temporal changes in cellular differentiation including a prolonged phase of endochondral calcification (Namkung-Matthai et al., 2001). This observation was also established for the mandible (Islam et al., 2005). However, no fractures were created in our model and we suggested two causes for this chondroitic aspect: (i) bone undergoing cartilaginous metaplasia, or (ii) rats showing vestiges of mandible cartilages not yet ossified. No alteration of the collagen fibres distribution was noted in the vitamin-D insufficient rats, confirming a previously established study (Maehata et al., 2005).

Exploring bone cell activity, our study not only confirms the presence of the osteoclastic activity in this osteoporotic model (Islam et al., 2005), but also reveals osteoblasts which are marked with the anti-apoptotic antibody especially in the ov-ob group. Bone microarchitectural alteration may be due to double bone cell disequilibrium, as shown in other studies (Gu et al., 2005; Hakeda, 2006; Narayana et al., 2006; Saintier et al., 2006). In fact, it has been demonstrated that osteoblast activity decreases with vitamin D insufficiency (Montero-Odasso and Duque, 2005) and estrogenic deficiency (Riggs et al., 2002) and that bone biopsies performed in elderly osteoporotic women have demonstrated decreased bone formation rates due to diminished osteoblast function (Marie et al., 1989). On the other hand, osteoclast activity is known to be enhanced by estrogenic deficiency (Islam et al., 2005) and vitamin D deficiency either in vivo or in vitro (Russel et al., 2006).

The use of the X-ray diffraction to explore the bone mineral phase was previously established (Sasaki and Sudoh, 1997). In our study, the lattice dimension of the mineral crystals and crystallite size were measured by the X-ray diffraction and were the same in all samples. This leads us to conclude that mineralization is not altered in any of these groups. This data was also established in other studies (Roudebush et al., 1993; Boivin and Meunier, 2003). Although, severe vitamin D deficiency causes rickets or osteomalacia, in which the osteoid is not mineralized, less severe vitamin D deficiency causes an increase of serum PTH leading to bone resorption, osteoporosis and fractures (Lips, 2006). In our experimental procedure, vitamin D obtained from food may be the cause of this attenuated deficiency and was enough to preserve the mineralization process.

In summary, the originality of this study is to validate a new model of osteoporotic animal by associating two factors: estrogens deficiency and vitamin D insufficiency. While mandibular weight analysis, confirmed by the immunohistochemical approach,

suggested that only the ov-ob group was significantly affected by the treatment, structural analysis showed similar data between ovariectomized groups compared to sham-operated ones. The mineral phase analysis did not find any difference between the groups studied. Although this model requires quantitative assessment and further longitudinal evaluation to indicate other differences between the groups, it seems to be adequate to study mandibular osteoporosis.

Acknowledgements. Samir Boukottaya (Faculty of Dental Medicine of Monastir, Tunisia) is acknowledged for English assistance.

References

- Bianchi A. and Sanfilippo F. (2002). Osteoporosis: the effect on mandibular bone resorption and therapeutic possibilities by means of implant prostheses. *Int. J. Period. Rest. Dent.* 22, 231-239.
- Boivin G. and Meunier P.J. (2003). The mineralization of bone tissue: a forgotten dimension in osteoporosis research. *Osteoporos Int.* 14 Suppl 3, S19-24.
- Carlsten H. (2005). Immune responses and bone loss: the estrogen connection. *Immunol. Rev.* 208, 194-206.
- Cesnjaj M., Stavljenic A. and Vukicevic S. (1991). Decreased osteoinductive potential of bone matrix from ovariectomized rats. *Acta. Orthop. Scan.* 62, 471-475.
- Correa P.H., Leite M.O., Borelli A. and Wajchenberg B.L. (1992). Effect of testosterone on bone mineralization of the hypophosphataemic rat. *Acta Endocrinol. (Copenh.)* 126, 510-514.
- Dervis E. (2005). Oral implications of osteoporosis. *Oral Surg. Oral Med. Oral Pathol. Oral Radiol. Endod.* 100, 349-356.
- Epstein S. (2006). The problem of low levels of vitamin D and osteoporosis: use of combination therapy with alendronic acid and colecalciferol (vitamin D3). *Drugs Aging* 23, 617-625.
- Fairney A., Fry J. and Lipscomb A. (1979). The effect of darkness on vitamin D in adults. *Postgrad. Med. J.* 55, 248-250.
- Gu G., Hentunen T.A., Nars M., Harkonen P.L. and Vaananen H.K. (2005). Estrogen protects primary osteocytes against glucocorticoid-induced apoptosis. *Apoptosis* 10, 583-595.
- Hakeda Y. (2006). Action of glucocorticoid on bone-forming and bone-resorbing cells. *Clin. Calcium* 16, 1817-1822.
- Hara T., Sato T., Oka M., Mori S. and Shirai H. (2001). Effects of ovariectomy and/or dietary calcium deficiency on bone dynamics in the rat hard palate, mandible and proximal tibia. *Arch. Oral Biol.* 46, 443-451.
- Ikeo T., Kamada A. and Goda S. (2007). Osteoporosis and oral biology. *Clin. Calcium* 17, 150-156.
- Islam A.A., Rasubala L., Yoshikawa H., Shiratsuchi Y. and Ohishi M. (2005). Healing of fractures in osteoporotic rat mandible shown by the expression of bone morphogenetic protein-2 and tumour necrosis factor-alpha. *Br. J. Oral Maxillofac. Surg.* 43, 383-391.
- Kalu D.N. (1991). The ovariectomized rat model of postmenopausal bone loss. *Bone Miner.* 15, 175-192.
- Kuroda S., Mukohyama H., Kondo H., Aoki K., Ohya K., Ohya T. and Kasugai S. (2003). Bone mineral density of the mandible in ovariectomized rats: analyses using dual energy X-ray absorptiometry and peripheral quantitative computed tomography. *Oral Dis.* 9, 24-28.
- Lee Y.H., Hyun S.H. and Choung S.Y. (2006). Effect of herbal extract mixture on menopausal urinary incontinence in ovariectomized rats. *Biofactors* 26, 171-178.
- Lerner U.H. (2006). Inflammation-induced bone remodeling in periodontal disease and the influence of post-menopausal osteoporosis. *J. Dent Res.* 85, 596-607.
- Li X. and Nishimura I. (1994). Altered bone remodeling pattern of the residual ridge in ovariectomized rats. *J. Prosthet. Dent.* 72, 324-330.
- Lien T.F., Chen W., Hsu Y.L., Chen H.L. and Chiou R.Y. (2006). Influence of soy aglycon isoflavones on bone-related traits and lens protein characteristics of ovariectomized rats and bioactivity performance of osteoprogenitor cells. *J. Agric Food Chem.* 54, 8027-8032.
- Lips P. (2006). Vitamin D physiology. *Prog. Biophys. Mol. Biol.* 92, 4-8.
- Maehata Y., Takamizawa S., Ozawa S., Kato Y., Sato S., Kubota E. and Hata R.I. (2005). Both direct and collagen-mediated signals are required for active vitamin D3-elicited differentiation of human osteoblastic cells: roles of osterix, an osteoblast-related transcription factor. *Matr. Biol.* 25, 47-85.
- Marie P.J., Sabbagh A., De Vernjoul M.C. and Lomri A. (1989). Osteocalcin and deoxyribonucleic acid synthesis in vitro and histomorphometric indices of bone formation in postmenopausal osteoporosis. *J. Clin. Endocrinol. Metab.* 69, 272-279.
- Mastaglia S.R., Pellegrini G.G., Mandalunis P.M., Gonzales Chaves M.M., Friedman S.M. and Zeni S.N. (2006). Vitamin D insufficiency reduces the protective effect of bisphosphonate on ovariectomy-induced bone loss in rats. *Bone* 39, 837-844.
- Montero-Odasso M. and Duque G. (2005). Vitamin D in the aging musculoskeletal system: an authentic strength preserving hormone. *Mol. Asp. Med.* 26, 203-219.
- Moriya Y., Ito K. and Murai S. (1998). Effects of experimental osteoporosis on alveolar bone loss in rats. *J. Oral Sci.* 40, 171-175.
- Namkung-Matthai H., Appleyard R., Jansen J., Hao Lin J., Maastricht S., Swain M., Mason R.S., Murrell G.A.C., Diwan A.D. and Diamond T. (2001). Osteoporosis influences the early period of fracture healing in a rat osteoporotic model. *Bone* 28, 80-86.
- Narayana Murthy P.S., Sengupta S., Sharma S. and Singh M.M. (2006). Effect of ormeloxifene on ovariectomy-induced bone resorption, osteoclast differentiation and apoptosis and TGF beta-3 expression. *J. Steroid Biochem. Mol. Biol.* 100, 117-128.
- Raisz L.G. (2005). Pathogenesis of osteoporosis: concepts, conflicts, and prospects. *J. Clin. Invest.* 115, 3318-3325.
- Riggs B.L., Khosla S. and Melton L.J. (2002). Sex steroids and the construction and conservation of the adult skeleton. *Endocr. Rev.* 23, 279-302.
- Roudebush R.E., Magee D.E., Bensley D.N., Bendele A.M. and Bryant H.U. (1993). Effect of weight manipulation on bone loss due to ovariectomy and the protective effects of estrogen in the rat. *Calcif. Tissue Int.* 53, 61-64.
- Russell R.G., Espina B. and Hulley P. (2006). Bone biology and the pathogenesis of osteoporosis. *Curr. Opin. Rheumatol.* 18 (Suppl 1), S3-10.
- Saintier D., Khanine V., Uzan B., Ea H.K., de Vernejoul M.C. and Cohen-Solal M.E. (2006). Estradiol inhibits adhesion and promotes apoptosis in murine osteoclasts in vitro. *J. Steroid Biochem. Mol. Biol.* 99, 165-173.
- Sasaki N. and Sudoh Y. (1997). X-ray pole figure analysis of apatite crystals and collagen molecules in bone. *Calcif. Tissue Int.* 60, 361-367.

Mandible bone of ovariectomized rats under vitamin D insufficiency

- Shirai H., Sato T., Oka M., Hara T. and Mori S. (2002). Effect of calcium supplementation on bone dynamics of the maxilla, mandible and proximal tibia in experimental osteoporosis. *J. Oral Rehabil.* 29, 287-294.
- Tanaka M., Ejiri S., Toyooka E., Kohno S. and Ozawa H. (2002). Effect of ovariectomy on trabecular structures of rat alveolar bone. *J Periodontal Res.* 37, 161-165.
- Tromp A.M., Bravenboer N., Tanck E., Oostlander A., Holzmann P.J., Kostense P.J., Roos J.C., Burger E.H., Huiskes R. and Lips P. (2006). Additional Weight Bearing during Exercise and Estrogen in the Rat: The Effect on Bone Mass, Turnover, and Structure. *Calcif Tissue Int.* 79, 404-415.
- Wactawski-Wende J. (2001). Periodontal diseases and osteoporosis: association and mechanisms. *Ann. Periodontol.* 6, 197-208.
- Weitzmann M.N. and Pacifici R. (2006). Estrogen deficiency and bone loss: an inflammatory tale. *J. Clin. Invest.* 116, 1186-1194.
- Wronski T.J., Lowry P.L., Walsh S.S., Ignaszewski L.A. (1985). Skeletal alterations in ovariectomised rats. *Calcif. Tissue Int.* 37, 324-328.

Accepted October 31, 2007