Histol Histopathol (2006) 21: 511-518
DOI: 10.14670/HH-21.511

http://www.hh.um.es

Histology and Histopathology
Cellular and Molecular Biology

Involvement of tenascin-C and PG-M/versican in flexor tenosynovial pathology of idiopathic carpal tunnel syndrome

M. Tsujii[1], H. Hirata[1], T. Yoshida[2], K. Imanaka-Yoshida[2], A. Morita[3] and A. Uchida[1]

[1]Department of Orthopaedic Surgery, Faculty of Medicine, Mie University, Tsu, Mie, Japan,
[2]Department of Pathology, Faculty of Medicine, Mie University, Tsu, Mie, Japan and
[3]Department of Orthopaedic Surgery, Suzuka Kaisei General Hospital, Suzuka, Mie, Japan

Summary. Increased intra-carpal-tunnel pressure due to swelling of the flexor tenosynovium is the most probable pathological mechanism of idiopathic carpal tunnel syndrome (CTS). To clarify the role of tenascin-C and PG-M/versican, which have often been found to be involved in tissue remodeling and vascular stenosis in the pathogenesis of CTS, we histologically and biochemically examined the production of extracellular matrix in the flexor tenosynovium from 40 idiopathic CTS patients. Tenascin-C was temporarily expressed in the vessel wall, synovial lining and fibrous tissue, with expression regulated differently in each tissue. Tenascin-C expression by vessels correlated with disease duration and appeared to be involved in vascular lesion pathology. Morphometric analysis showed that tenascin-C expression by small arteries is correlated with PG-M/versican expression in surrounding connective tissue. PG-M/versican was also present at the neointima of severely narrowed vessels.

Although tenascin-C expression by synovial lining and connective tissue shows marked regional variation and seems inconsistent, in vitro examination suggested that tenascin-C production by these tissues is regulated in response to mechanical strain on the flexor tenosynovium.

Key words: PG-M/versican, Tenascin-C, Idiopathic carpal tunnel syndrome, Tenosynovial thickening, Vascular lesion

Offprint request to: Dr. Hitoshi Hirata, Department of Orthopaedic Surgery, Faculty of Medicine, Mie university, 2-174, Edobashi, Tsu, Mie prefecture, Japan. e-mail: h-hirata@clin.medic.mie-u.ac.jp

Introduction

Idiopathic carpal tunnel syndrome (CTS) needing surgery is estimated to occur in as many as 4% of the general population (Pananicholoaou et al., 2001; Atroshi et al., 2003).

Various anatomical, pathological and physiological disorders can lead to compression of the median nerve in the carpal tunnel (Szabo, 1991). However, no particular underlying abnormalities or illness can be identified in most cases, and idiopathic CTS is therefore classified. Idiopathic CTS is viewed as resulting from either a decrease in size of the carpal tunnel or an increase in the volume of the contents. Previous studies have demonstrated no significant differences between patients with and without CTS with regard to morphometrics or biomechanical behaviors of the transverse carpal ligament (Tanzer, 1959; Lin et al., 1983; Nakamichi and Tachibana, 1998). MRI studies on idiopathic CTS have demonstrated an increased distance between tendons and volar bowing of the transverse carpal ligament due to tenosynovial swelling (Britz et al., 1995; Allman et al., 1997; Brahme et al., 1997). Recent reports including our own have demonstrated that idiopathic CTS is associated with rapidly progressing hypertrophic remodeling of small arteries and reconstitution of connective tissues in the flexor tenosynovium (Ettema et al., 2004; Hirata et al., 2004, 2005; Jinrok et al., 2004). In addition, a variety of inflammatory mediators including PGE2, interleukins and proteases were found to be involved in the pathological events of idiopathic CTS (Tucci et al., 2001; Freeland et al., 2002; Hirata et al., 2004, 2005). In addition, the activation level of MMP2 was significantly correlated with subjective symptom severity (Hirata et al., 2005). Idiopathic CTS thus seems to start as a flexor tenosynovial pathology that in turn causes an increase in intra-carpal-tunnel pressure and has a secondary effect on median nerve function. However, little is known

about the relationships between remodeling of vessels and connective tissues and how these cause volume increases in the flexor tenosynovium. While a complex interplay of numerous molecules is required for tissue remodeling, two molecules with considerable potential for important roles are tenascin-C and PG-M/versican. These molecules have been found to be involved in vascular lesions and connective tissue remodeling in a variety of diseases, including pulmonary fibrosis, vascular diseases and malignant tumors (Jones and Rabinovitch, 1996; Jones et al, 1997a; Yoshida et al., 1999; Jones and Jones, 2000a,b; Imanaka-Yoshida, 2001).

The aim of the present study was to biochemically and histologically examine the flexor tenosynovium harvested during open carpal tunnel release in order to identify the roles of tenascin-C and PG-M/versican in the tenosynovial swelling in idiopathic CTS.

Materials and methods

Subjects

This study was approved by the ethical committee of Mie University and Suzuka Kaisei General Hospital.

The study group comprised 40 patients (12 men, 28 women) who were treated surgically for idiopathic CTS. The mean age of the patients was 53.2 years (range, 31-79 years). Patients with a history of diabetes mellitus, inflammatory arthritis, autoimmune disorders, thyroid abnormalities or renal failure were excluded from the study. Patients were divided into 4 clinical groups based on duration from symptom onset to time of surgery: group A, <4 months; group B, 4-6 months; group C, 7-12 months; and group D, >12 months. Demographics of patients in each group are shown in Table 1. Most patients in group D had experienced mild pain and numbness in the median nerve distribution for years, but abrupt exacerbation of symptoms had led them to choose surgery.

Written informed consent was obtained from all patients and a standard open carpal tunnel release and tenosynovectomy was performed. Tenosynovial specimens were divided into 3 pieces. One piece was fixed in 10% formalin immediately and sent to the pathology department, the second was used for biochemical analysis, and the third for cell culture.

Table 1. Demographics of the patients in each group.

GROUP	A	B	C	D	TOTAL
number	8	12	8	12	40
mean age	45.3	50.7	57.1	58.3	53.2
gender (male/female)	3/5	5/7	2/6	2/10	12/28

Histological analysis

Specimens were embedded in paraffin, cut into 5 μm-thick sections, and stained with hematoxylin and eosin (HE) or Sirius red. After dewaxing in xylene and rehydration in graded methanol (99% to 70% (v/v)) in distilled water, HE staining was performed.

Immunohistochemistry

Immunohistochemical analysis was performed using polyclonal rabbit anti-tenascin-C antibody (raised by TY (Yoshida et al., 1999)), monoclonal anti-PG-M/versican antibody (MBL, Nagoya, Japan) and monoclonal anti-type III collagen antibody (Daiichi Pharmaceutical Co., Tokyo, Japan). Samples from groups A-D were run in parallel in each experiment. Specimens were dewaxed in xylene and rehydrated in graded methanol (99% to 70% (v/v)) in distilled water. Endogenous peroxidase activity was quenched by 30 min incubation with 3% (v/v) H_2O_2 in 99% methanol. For anti-tenascin-C antibody, antigenic sites were unmasked by incubation with 0.4% (v/v) pepsin in 0.02 N hydrogen chloride. A solution of 1% bovine serum albumin (BSA) was applied to sections (15 min, 25°C) to block non-specific binding sites. BSA was then tipped off and specimens were incubated for 2 h at 25°C with each antibody (1:100). Bound primary antibodies were detected by applying 1:100 secondary biotinylated goat anti-rabbit and anti-mouse antibodies (Dako Japan, Kyoto, Japan) for 30 min at 25°C. Visualization of bound antibodies was achieved by incubating sections with a solution of avidin-biotin horseradish peroxidase complex (Dako Japan) and reacting with a 3-3' diaminobenzidine (DAB) or DAB nickel tetrachloride/H2O2 substrate. Between incubation steps, sections were dip immersion washed (3x5 min wash) in phosphate-buffered saline (PBS; pH 7.2) to eliminate excess non-bound antibody or reagent. Sections were counterstained using hematoxylin. Control sections were not incubated with primary antibodies. In all cases, control sections showed no evidence of staining or color reaction under microscopic examination.

Morphometric analysis

Specimens were viewed using a BX50 microscope (Olympus, Tokyo, Japan) equipped with a video camera. Digitized images were provided on the screen of a computer and morphometric analysis was performed using Lumina Vision version 1.11 software for Windows (Mitani Shoji Co., Fukui, Japan).

To examine relationships between tenascin-C expression in the vessel wall and PG-M/versican expression in surrounding connective tissue, morphometric analyses were performed. A total of 40 fields containing small arteries with diameters of 50-400 μm were selected in specimens stained with anti-tenascin-C antibody by author TS, who was blinded to

clinical data and origins of specimens. An identical 40 fields were carefully searched from serial specimens stained with anti-PG-M/versican antibody. The percentage of tenascin-C-expressing areas in the arterial wall (i.e., proportion of vessel wall stained by antibody to tenascin-C) was calculated as the sum total of stained areas divided by the total area of arterial wall. Percentage of PG-M/versican-expressing areas in connective tissue surrounding arteries was calculated as the sum total of stained areas divided by the total area of connective tissue.

Biochemical analysis

Biopsy specimens were snap frozen in liquid nitrogen, homogenized using a Cryopress (Microtech, Chiba, Japan) and the supernatant preserved at -80°C. Analysis of supernatant for normalization of protein content was performed by microassay (Pierce Biotechnology, Rockford, USA). Quantitative analysis of tenascin-C (MBL, Nagoya, Japan) was performed using enzyme-linked immunosorbent assay (ELISA). Duplicate samples were analyzed. Sensitivity of the method was 0.375 ng/ml. Intra- and interassay coefficients of variation were <5 %.

Preparation of tenosynovial fibroblasts and analysis of the effects of mechanical strain on cells

Tenosynovium was minced with a scalpel under sterile conditions and then incubated in F-12 Ham's medium (GIBCO Laboratories, MA, USA) containing 10% fetal bovine serum (FBS; Canadian International, Canada), streptomycin (100 mg/ml), 300 units/ml collagenase (St. Louis, MO, USA) and 5000 units/ml dispase under 95% air 5% CO_2 atmosphere at 37°C for 12 h. Isolated cells were then cultured in Dulbecco's modified Eagle's medium (DMEM) containing 10% FBS and streptomycin (100 mg/ml) on type I collagen-coated dishes. When primary culture cells reached confluence, cells were removed from flasks with 0.02% EDTA in PBS and re-plated in Flex I culture plates that have flexible bottoms of silicone elastomer coated with type I collagen (Flexcell International NC, USA) at an initial density of $1x10^5$ cells/ml, and incubated in DMEM containing 10% FBS under the same conditions used previously.

Cells were subjected to mechanical strain using the Flexercell strain unit (Flexercell Int. Corp.) (Banes et al., 1985). A vacuum was applied to the rubber-bottomed plates, resulting in a 20% reproducible deformation of the membrane, and thus, in biaxial stretching of attached cells. Cells were submitted to cyclic stretching (0.5 Hz) in a humidified incubator under the above-mentioned conditions for 36 h. No stretching was applied to the control group. The plate had 6 wells, and supernatant from each of the wells was collected and centrifuged to remove cells and cell fragments every 6 h. These were preserved at -80°C. Levels of tenascin-C were determined using an ELISA kit (MBL).

Statistical analysis

StatView 5.0 for Windows software (SAS Institute, NC, USA) was used for statistical analysis. Data were analyzed using the Mann-Whitney U-test or by calculating Spearman's coefficient of rank correlation. Values of $p<0.05$ were deemed statistically significant.

Results

Histological analysis

As we reported previously, proliferative arteriosclerosis, villous thickening of synovial lining and connective tissue fibrosis and degeneration occur and advance with disease progression in the flexor tenosynovium in idiopathic CTS (Hirata et al., 2004, 2005).

Tenascin-C expression pattern changes with disease progression

Hypertrophic remodeling is seen predominantly in small arteries of 50-400 μm diameter. In group A, although most vessels displayed normal architecture, diffuse and intense immunostaining for tenascin-C was noted in vessel walls (Fig. 1a). In group B, many small arteries displayed luminal narrowing due to hypertrophic remodeling and anti-tenascin-C staining was confined to the adventitia and intima (Fig. 1b). In group C, most vessels with tunica media displayed marked medial and intimal thickening with severe luminal narrowing. Some vessels were obstructed by thrombi (Fig. 2). At this stage, tenascin-C staining was observed only in the hypertrophied intima (Fig. 1c). Although specimens from group D exhibited histological findings similar to group C, a noticeable difference in the anti-tenascin-C staining pattern was present between the two groups. In contrast to the uniformly low immunostaining for tenascin-C in group C, a fraction of small arteries in group D showed high and diffuse tenascin-C deposition (Fig. 1d).

Anti-tenascin-C immunostaining in connective tissue and synovial lining

In contrast to anti-tenascin-C immunostaining in small arteries, immunostaining in connective tissue showed little correlation to disease duration. The intensity of immunostaining in the connective tissue showed marked regional variation and little correlation with staining in neighboring vessels (Fig. 3a,b). Since connective tissues including synovial lining compose most of the tenosynovium, these ELISA results reflect tenascin-C expression in connective tissue. Quantitative analysis with ELISA demonstrated that tenascin-C expression varied between specimens and did not show

any significant difference among the 4 groups (Fig. 3c).

Role of mechanical strain in upregulation of tenascin-C expression by connective tissue

To address the effect of mechanical strain on tenascin-C expression by tenosynovium in patients with CTS, an in vitro study was performed. Tenascin-C production by cultured tenosynovial fibroblasts from CTS patients was significantly enhanced by mechanical stress on cells (Fig. 4). Tenascin-C expression by tenosynovial fibroblasts thus seems to change in response to mechanical strain.

Both fibrous tissue and synovial lining express PG-M/versican

In groups A and B, PG-M/versican presented both diffusely and intensely in connective tissue and synovial lining. In both groups, vessels did not show immunostaining for PG-M/versican except for neointima in group B (Fig. 5a,b). In group C, immunostaining for PM-G/versican was markedly decreased in all tissues except for the neointima of severely narrowed vessels (Fig. 5c). In contrast, in group D, PM-G/versican was highly and diffusely expressed in areas where small arteries with high tenascin-C expression exist (Fig. 5d,h). Morphometric analysis was performed to analyze relationships between tenascin-C expression level in small arteries and PG-M/versican expression in surrounding connective tissues, indicating significant positive correlations (Figs. 5, 6).

Discussion

Although the existence of histological changes pathognomonic to idiopathic CTS has long been a matter of contention (Faithful et al., 1986; Neal et al., 1987; Scelsi et al., 1989; Schuind et al., 1990; Fuchs et al., 1991; Kerr et al., 1992; Llunch, 1992; Gross et al., 1995; Nakamichi and Tachibana, 1998; Chell et al., 1999; Shum et al., 2002), recent reports including our own have clearly demonstrated that drastic remodeling of small arteries and connective tissue takes place and progresses with disease in the flexor tenosynovium (Ettema et al., 2004; Hirata et al., 2004, 2005; Jinrok et al., 2004). Furthermore, a wide variety of inflammatory mediators including cytokines, prostaglandins and

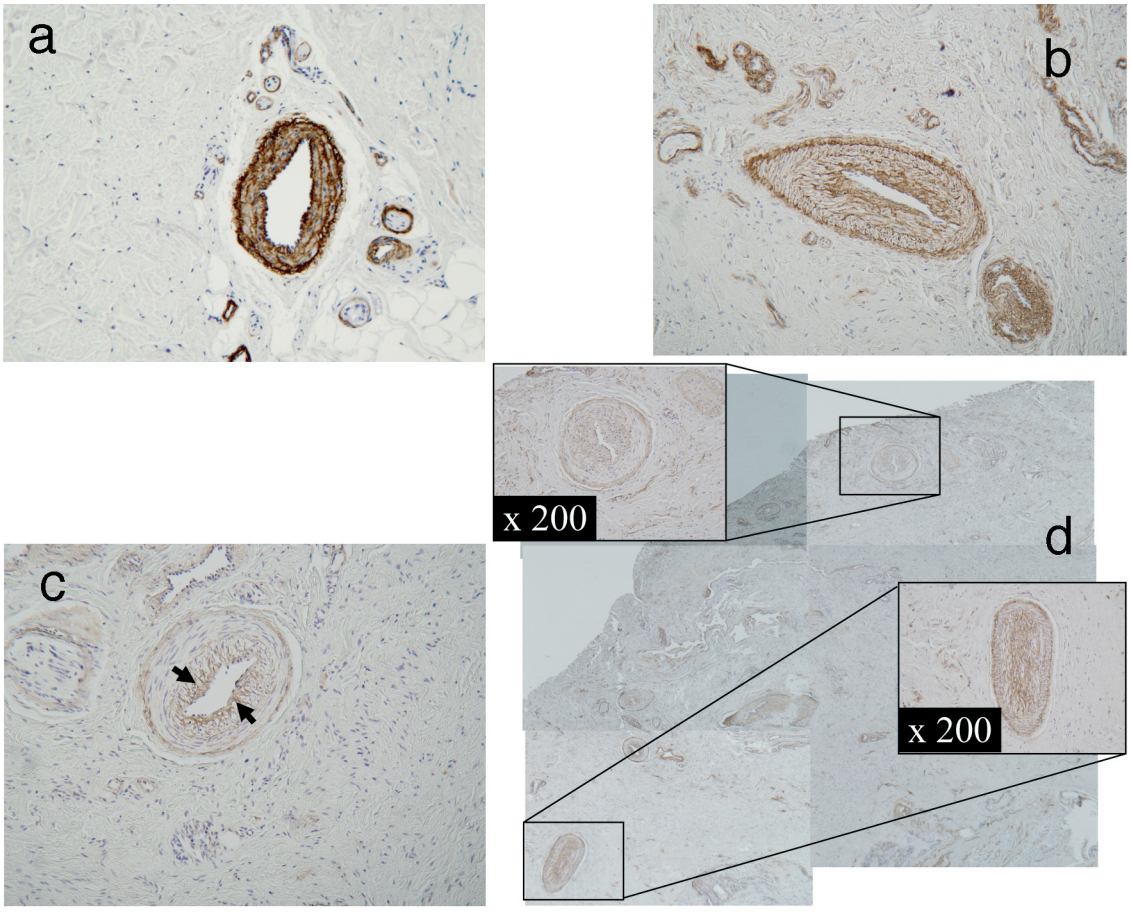

Fig. 1.
Immunolabeling for tenascin-C in the small arteries. **a.** A representative artery from group A. The vessel retains normal architecture and highly expresses tenascin-C. **b.** A representative artery from group B which shows marked vascular narrowing due to hypertrophic remodeling. Both adventitia and neointima highly express tenascin-C while that of tunica media is moderate. **c.** A representative artery from group C. Although the vessel shows marked hypertrophic remodeling, only neointima moderately expresses tenascin-C (black arrows). **d.** Arteries in group D show marked regional variation in tenascin-C expression.
a-c: x 200; d: x 40

proteases have been found to be involved in tenosynovial pathology (Tucci et al., 2001; Freeland et al., 2002; Hirata et al., 2004, 2005). We recently found that, although tenosynovium in idiopathic CTS lacks neutrophilic or lymphocytic infiltration, a number of mast cells invade the tenosynovium and induce pathological events in both vessels and connective tissues (unpublished data). As demonstrated by recent clinical studies, increases in tenosynovial volume in a confined osseo-fibrous compartment of the carpal tunnel result in abnormally high interstitial pressures, in turn causing median nerve damage (Okutsu et al., 2001; Yoshida and Okutsu, 2004). In this context, idiopathic CTS is primarily a disease of the tenosynovium, and median nerve damage is a secondary phenomenon. In fact, a previous study demonstrated that 8-18% of patients with typical symptoms of CTS display normal nerve conduction velocity (NCV), but can still benefit from treatment in the same way as those with abnormal EMG test results (Wright and Liggett, 2003). An understanding of the mechanisms of increased tenosynovial volume is thus the key to elucidating the pathogenesis of idiopathic CTS.

Tenascin-C is a glycoprotein abundantly expressed in the embryo during chondrogenesis and neurogenesis, but is not expressed in most normal adult tissues. However, tenascin-C transiently reappears during inflammation, tissue repair/regeneration and tumor invasion (Jones and Jones, 2000a; Jones, a,b). Several studies have demonstrated that tenascin-C induces vascular smooth muscle cell proliferation and neointimal formation, thereby promoting hypertrophic vascular remodeling (Jones and Rabinovitch, 1996; Jones et al., 1997a,b). Our previous study showed that tenascin-C was expressed diffusely and intensely by the coronary artery within 1 month after percutaneous transluminal

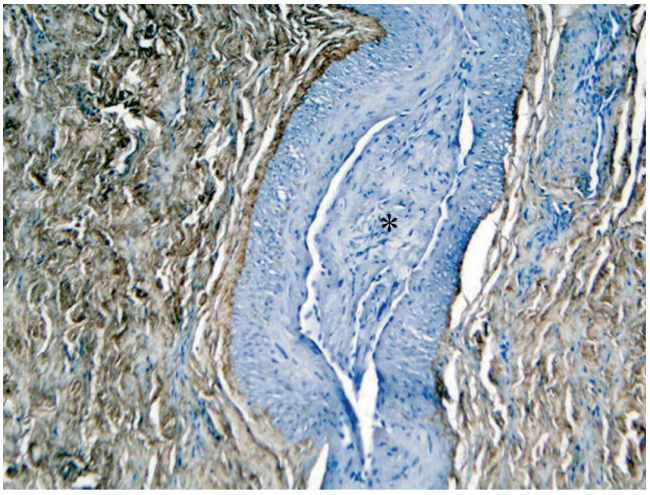

Fig. 2. Immunolabeling for type III collagen. Note that the vessel is occluded by a thrombus, indicated with an asterisk. x 200

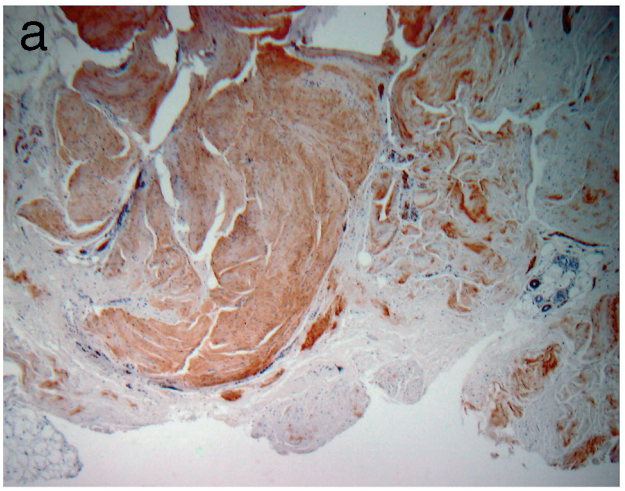

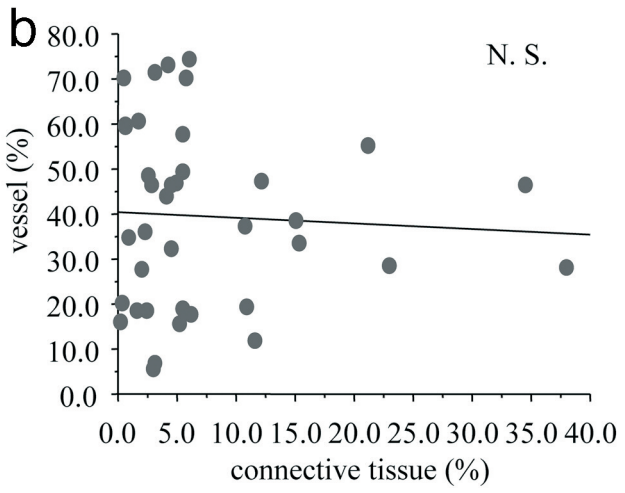

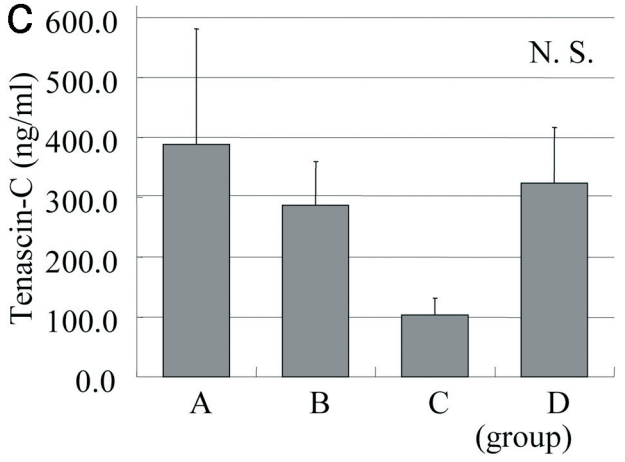

Fig. 3. a. Immunoreactivity against tenascin-C in the connective tissue. Note that tenascin-C expression in connective tissue is not uniform. **b.** Quantitative analysis of tenascin-C expression in each group by ELISA. There was not any statistically significant difference between the four groups. **c.** Correlation between tenascin-C expression by vessels and by the surrounding connective tissue. x 45

coronary angioplasty, and strongly induces neointimal formation (Imanaka-Yoshida et al., 2001). In the present study, tenascin-C was highly expressed in small arteries during the early phase of idiopathic CTS. Although staining intensity decreased in the tunica media during the intermediate phase, both the adventitia and intima continued to express tenascin-C at high levels. Even in the late phase, when neither the adventitia nor media expressed tenascin-C, the molecule was found deposited between intimal cells. Tenascin-C thus appears to be involved in hypertrophic remodeling of arteries, in a similar fashion to coronary or pulmonary artery disease.

In contrast, tenascin-C expression in connective tissue did not correlate with disease duration. As indicated by in vitro analysis, expression of tenascin-C by tenosynovial fibroblasts appears to be regulated in response to mechanical strain. Previous studies have demonstrated that tenascin-C gene expression can be

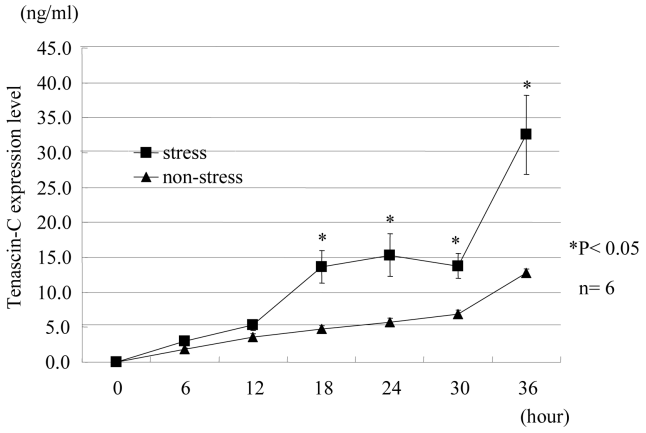

Fig. 4. Effect of mechanical strain on tenascin-C production by cultured synovial fibroblasts. Quantitative analysis by ELISA. *p<0.05; n=6

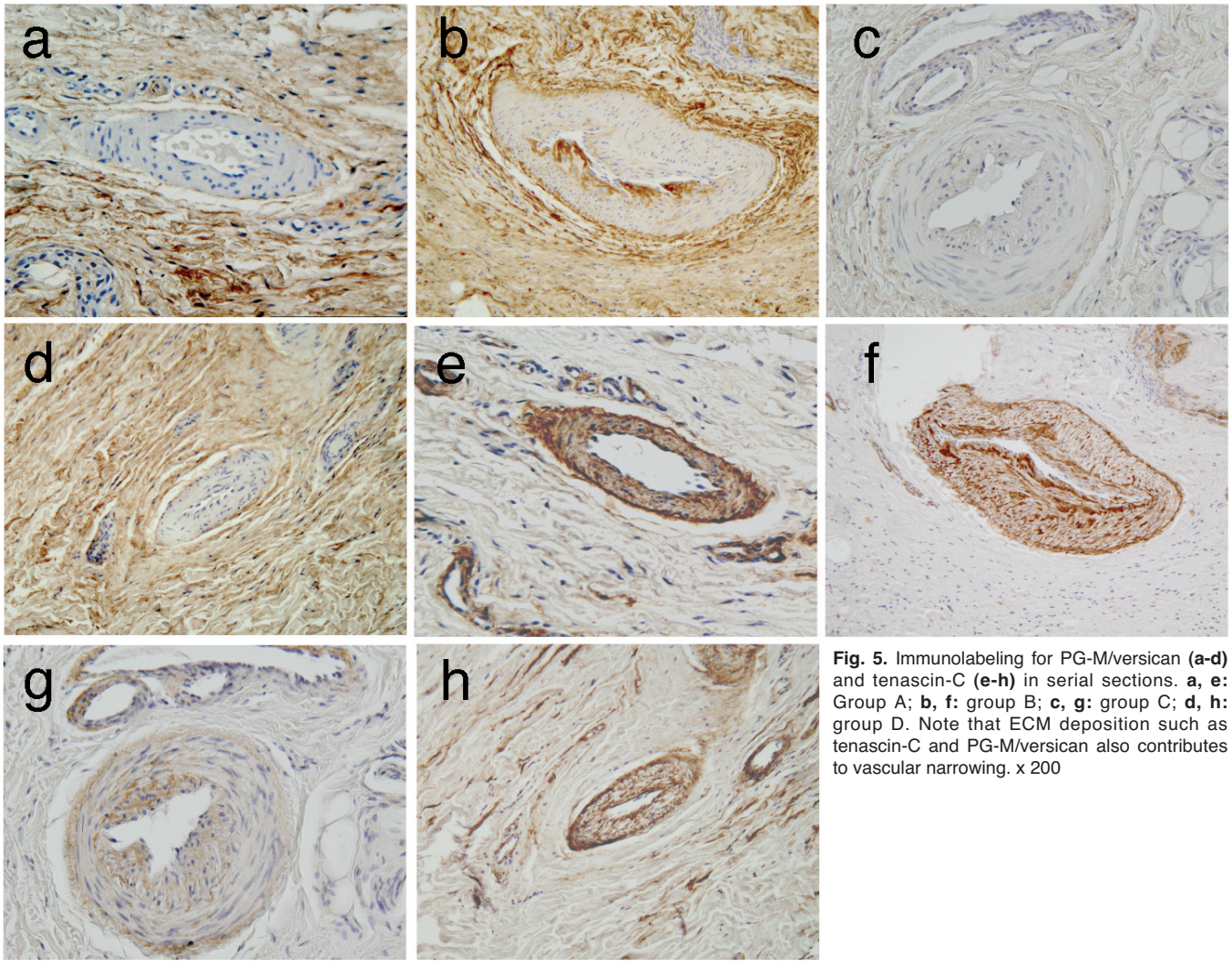

Fig. 5. Immunolabeling for PG-M/versican **(a-d)** and tenascin-C **(e-h)** in serial sections. **a, e:** Group A; **b, f:** group B; **c, g:** group C; **d, h:** group D. Note that ECM deposition such as tenascin-C and PG-M/versican also contributes to vascular narrowing. x 200

mechanosensitive, and that it occurs on most occasions at the level of the gene promoter, with different promoter motifs and transcription factors coming into play depending on the cell type (Jones and Jones, 2000a,b). In idiopathic CTS, intra-carpal tunnel pressure increases up to 30 mmHg (Gelberman et al., 1981). Thus, not only the median nerve but also the tenosynovium are placed under high hydrodynamic pressure. Marked regional variation in tenascin-C expression in the tenosynovium may reflect regional variations in pressure within the carpal tunnel. Our previous morphometric analysis with MRI demonstrated that tenosynovial volume is significantly smaller in group C than group A and B (unpublished data). We believe that the marked reduction in tenascin-C expression noted in group C, as demonstrated by both quantitative analysis with ELISA and qualitative analysis by immunohistochemistry, reflects lower intra-carpal tunnel pressure in this group. In the present study, the role of tenascin-C in connective tissue could not be identified. Considering the clinical observation that subjective symptom severity tends to worsen after strenuous use of the hand, tenascin-C in connective tissue may be directly or indirectly involved in pain generation in idiopathic CTS.

The most intriguing finding in the present study was that tenascin-C expression in small arteries was significantly correlated with PG-M/versican expression in the surrounding connective tissue. Since PG-M/versican has a significant mass effect due to a highly interactive and water entrapping nature, the molecule would be expected to cause the extracellular matrix to swell (Wight, 2002). In fact, our morphometric study using MRI demonstrated that tenosynovial volume decreases significantly in the order of group A, B and C, consistent with the changes in PG-M/versican expression level found in this study. In addition, tenosynovial volume significantly increased in group D, in which PG-M/versican expression increases again in areas surrounding tenascin-C expressing arteries (data not shown). Notably, PG-M/versican was found to be highly expressed at the neointima, suggesting a role in vascular narrowing (Matsuura et al., 1996; Imanaka-Yoshida et al., 2001).

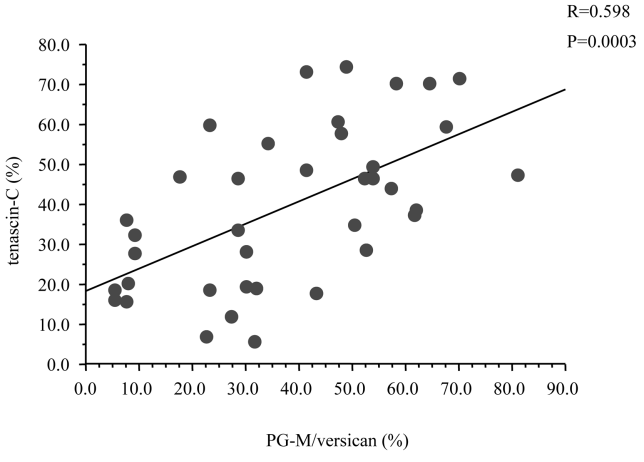

Fig. 6. Correlation between tenascin-C expression level in small arteries and PG-M/versican expression in surrounding connective tissues.

Recent biochemical studies have demonstrated that flexor tenosynovium from patients with idiopathic CTS contained significant concentrations of malondialdehyde bis diethyl acetal (Freeland et al., 2002). Ischemia reperfusion injury thus appears to be involved in the pathological mechanisms of idiopathic CTS. Both severe vascular narrowing and increased intra-carpal tunnel pressure due to tenosynovial swelling apparently contribute to vascular insufficiency in idiopathic CTS.

In conclusion, although the exact interaction between tenascin-C and PG-M/versican remains not entirely clear, these two molecules appear to play significant roles in the pathological mechanisms of idiopathic CTS. The significant volume effects of PG-M/versican lead to volume increases both in the vessel wall and in the flexor tenosynovim within the confined space of the carpal tunnel, thereby causing median nerve entrapment by the so-called compartment effect. Since tenosynovium contains matrix molecules other than PG-M/versican that produce the significant volume effect, such as hyaluronan, the interaction between tenascin-C and PG-M/versican is most likely not the only mechanism that induces tenosynovial swelling in idiopathic CTS.

References

Allmann K.H., Horch R., Uhl M., Gufler H., Altehoefer C., Stark G.B. and Langer M. (1997). MR imaging of the carpal tunnel. Eur. J. Radiol. 25, 141-145.

Atroshi I., Gummesson C., Johnsson R., McCabe S.J. and Ornstein E. (2003). Severe carpal tunnel syndrome potentially needing surgical treatment in a general population. J. Hand Surg. 28A, 639-644.

Banes A.J., Gilbert J., Taylor D. and Monbureau O. (1985). A new vacuum-operated stress-providing instrument that applies static or variable duration cyclic tension or compression to cells in vitro. J. Cell Sci. 75, 35-42.

Brahme S.K., Hodler J., Braun R.M., Sebrechts C., Jackson W. and Resnick D. (1997). Dynamic MR imaging of carpal tunnel syndrome. Skel. Radiol. 26, 482-487.

Britz G..W., Haynor D.R., Kuntz C., Goodkin R., Gitter A. and Kliot M. (1995). Carpal tunnel syndrome: correlation of magnetic resonance imaging, clinical, electrodiagnostic, and intraoperative findings. Neurosurgery 37, 1097-1103.

Chell J., Stevens A. and Davis T.R. (1999). Work practices and histopathological changes in the tenosynovium and flexor retinaculum in carpal tunnel syndrome in women. J. Bone Joint Surg. 81, 868-870.

Ettema A.M., Amadio P.C., Zhao C., Wold L.E. and An K.N. (2004). A histological and immunohistochemical study of the subsynovial connective tissue in idiopathic carpal tunnel syndrome. J. Bone Joint Surg. 86, 1458-1466.

Faithful D.K., Moir D.H. and Ireland J. (1986). The micropathology of the

typical carpal tunnel syndrome. J. Hand Surg. 11B, 131-132.

Freeland A.E., Tucci M.A., Barbieri R.A., Angel M.F. and Nick T.G.. (2002). Biochemical evaluation of serum and flexor tenosynovium in carpal tunnel syndrome. Microsurgery 22, 378-385.

Fuchs P.C., Nathan P.A. and Myers L.D. (1991). Synovial histology in carpal tunnel syndrome. J. Hand Surg. 16A, 753-758.

Gelberman R.H., Hergenroeder P.T., Hargens A.R., Lundborg G.N. and Akeson W.H. (1981). The carpal tunnel syndrome. A study of carpal canal pressures. J. Bone Joint Surg. 63, 380-383.

Gross A.S., Louis D.S., Carr K.A. and Weiss S.A. (1995). Carpal tunnel syndrome: a clinicopathologic study. J. Occup. Envion. Med. 37, 437-441.

Hirata H., Nagakura T., Tsujii M., Morita A., Fujisawa K. and Uchida A. (2004). The relationship of VEGF and PGE2 expression to extracellular matrix remodeling of the tenosynovium in the carpal tunnel syndrome. J. Pathol. 204, 605-612.

Hirata H., Tsujii M., Yoshida T., Imanaka-Yoshida K., Morita A., Okuyama N., Nagakura T., Sugimoto T., Fujisawa K. and Uchida A. (2005). MMP2 expression is associated with rapidly proliferative arteriosclerosis in the flexor tenosynovium and pain severity in carpal tunnel syndrome. J. Pathol. 205, 443-450.

Imanaka-Yoshida K., Matsuura R., Isaka N., Nakano T., Sakakura T. and Yoshida T. (2001). Serial extracellular matrix changes in neointimal lesions of human coronary artery after percutaneous transluminal coronary angioplasty: clinical significance of early tenascin-C expression. Virchows Arch. 439, 185-190.

Jinrok O., Zhao C., Amadio P.C., An K.N., Zobitz M.E. and Wold L.E. (2004). Vascular pathological changes in the flexor tenosynovium (subsynovial connective tissue) in the idiopathic carpal tunnel syndrome. J. Orthop. Res. 22, 1310-1315.

Jones F.S. and Jones P.L. (2000a). The tenascin family of ECM glycoproteins: structure, function, and regulation during embryonic development and tissue remodeling. Dev. Dyn. 218, 235-259.

Jones P.L. and Jones F.S. (2000b). Tenascin-C in development and disease: gene regulation and cell function. Matrix Biol. 19, 581-596.

Jones P.L., Cowan K.N. and Rabinovitch M. (1997a). Tenascin-C, proliferation and subendothelial fibronectin in progressive pulmonary vascular disease. Am. J. Pathol. 150, 1349-1360.

Jones P.L., Crack J. and Rabinovitch M. (1997b). Regulation of tenascin-C, a vascular smooth muscle cell survival factor that interacts with the alpha v beta 3 integrin to promote epidermal growth factor receptor phosphorylation and growth. J. Cell Biol. 139, 279-293.

Jones P.L. and Rabinovitch M. (1996). Tenascin-C is induced with progressive pulmonary vascular disease in rats and is functionally related to increased smooth muscle cell proliferation. Circ. Res. 79, 1131-1142.

Kerr C.D., Sybert D.R. and Albarracin N.S. (1992). An analysis of the flexor synovium in idiopathic carpal tunnel syndrome: report of 625 cases. J. Hand Surg. 17A, 1028-1030.

Lin R., Lin E., Engel J. and Bubis J.J. (1983). Histo-mechanical aspect of carpal tunnel syndrome. Hand 15, 305-309.

Llunch A.L. (1992). Thickening of the synovium of the digital flexor tendons: cause or consequence of the carpal tunnel syndrome? J. Hand Surg. 17B, 209-212.

Matsuura R., Isaka N., Imanaka-Yoshida K., Yoshida T., Sakakura T. and Nakano T. (1996). Deposition of PG-M/versican is a major cause of human coronary restenosis after percutaneous transluminal coronary angioplasty. J. Pathol. 180, 311-316.

Nakamichi K. and Tachibana S. (1998). Histopathlogy of the transverse carpal ligament and flexor tenosynovium in idiopathic carpal tunnel syndrome. J. Hand Surg. 23A, 1015-1024.

Neal N.C., McManners J. and Stirling G.A. (1987). Pathology of the flexor tendon sheath in the spontaneous carpal tunnel syndrome. J. Hand Surg. 12B, 229-232.

Okutsu I., Hamanaka I., Chiyokura Y., Miyauchi Y. and Sugiyama K. (2001). Intraneural median nerve pressure in carpal tunnel syndrome. J. Hand Surg. 26B, 155-156.

Pananicholoaou G.D., McCabe S.J. and Firell J. (2001). The prevalence and characteristics of nerve compression symptoms in the general population. J. Hand Surg. 26A, 460-466.

Scelsi R., Zanlungo M. and Tenti P. (1989). Carpal tunnel syndrome. Anatomical and clinical correlations and morphological and ultrastructural aspects of the tenosynovial sheath. Ital. J. Orthop. Traumatol. 15, 75-80.

Schuind F., Ventura M. and Pasteels J.L. (1990). Idiopathic carpal tunnel syndrome: histologic study of flexor tendon synovium. J. Hand Surg. 15A, 497-503.

Shum C., Parisien M., Strauch R.J. and Rosenwasser M.P. (2002). The role of flexor tenosynovectomy in the operative treatment of carpal tunnel syndrome. J. Bone Joint Surg. [Am] 84, 221-225.

Szabo R.M. (1991). Carpal tunnel syndrome-general. In: Operative nerve repair and reconstruction. Gelberman R. H. (ed). J.B. Lippincott, Philadelphia. pp. 939-948.

Tanzer R.C. (1959). The carpal-tunnel syndrome. A clinical and anatomical study. J. Bone Joint Surg. 41A, 626-634.

Tucci M., Sud V. and Freeland A. (2001). Compression of the median nerve in CTS is mediated by periods of acute synovial swelling. Biomed. Sci. Instrum. 37, 299-303.

Wight T.N. (2002). Versican: a versatile extracellular matrix proteoglycan in cell biology. Curr. Opin. Cell Biol. 14, 617-623.

Wright S.A. and Liggett N. (2003). Nerve conduction studies as a routine diagnostic aid in carpal tunnel syndrome. Rheumatology 42, 602-603.

Yoshida A. and Okutsu I. (2004). Relationship of carpal canal contents volume to carpal canal pressure in carpal tunnel syndrome patients. J. Hand Surg. 29B, 277-280.

Yoshida T., Yoshimura E., Numata H., Sakakura Y. and Sakakura T. (1999). Involvement of tenascin-C in proliferation and migration of laryngeal carcinoma cells. Virchows Arch. 435, 496-500.

Accepted December 30, 2005