

The influence of different fibrous supplements in the diet on ruminal histology and histometry in veal calves

A. Di Giancamillo, G. Bosi, S. Arrighi, G. Savoini and C. Domeneghini

Department of Veterinary Sciences and Technologies for Food Safety, University of Milan, Milan, Italy

Summary. The aim of this study was to determine whether the administration of four different solid feeds would influence selected morphological and morpho-functional aspects of the rumen mucosa in veal calves. The fibrous supplementation of the liquid diet of veal calves has been provided by recent EU formulation (EC Council Directive 91/629/1991; EC Council Directive 97/2/1997).

Twenty-five Holstein calves were assigned to either exclusively liquid diet (milk replacer, control), or pelleted feed, corn silage, extruded feed, dried corn silage. The morpho-functional effects of the fibre-containing diets were examined evaluating histological and histometrical characteristics of ruminal mucosa after the slaughter of calves.

There were slight to severe histological abnormalities in the rumens of all animals examined. The severe histological abnormalities were present in calves given pelleted feed, corn silage, and extruded feed. Dried corn silage caused less ruminal damage. We found that the length and epithelial thickness of ruminal papillae were higher in control veal calves than in dietary fibre-supplemented animals. The results of the present study, even if partially, support the EU prescription in the use of fibre diets in veal calves as integration of the traditional milk replacer diet.

Key words: Veal calves, Rumen, Histology, Histometry, Fibre supplements

Introduction

Veal calves are traditionally fed on milk replacer with restricted iron content to produce a light-coloured meat, which is specially appreciated by the consumers (Miltenburg et al., 1992). The milk replacer totally lacks any solid feed, and is administered until the veal calves

reach the optimal weight (at 5-6 months of age). This exclusively liquid diet combined with the isolated stall system of rearing contributes to a poor level of welfare in calves (Broom, 1991; Morrill, 1999). These young animals spend most of their active time nibbling inedible objects whereas calves offered solid feeds spend the same time eating and ruminating (Veissier et al., 1997). In addition, the lack of solid feeds in veal calves fed an all-liquid diet often leads to the massive presence of not fully developed ruminal papillae and rumen dysfunction (Scientific Veterinary Committee, Report on the welfare of calves, 1995). According Morisse et al. (1997), solid feeds when added to the liquid diet on the contrary stimulate rumen development, because they promote ruminal size increase, stimulate the growth of the ruminal papillae, as well as providing a substrate for the growing of microbiota, which in turn cooperate in digesting dietary fibres.

EU Council regulations regarding veal calves (91/629/EC Directive, 1991; 97/2/EC Directive, 1997) are exactly intended to improve both the well-being of these animals and the correct morpho-functional development of rumen. In particular, the 97/2/EC Directive stipulates that veal calves should be provided with a minimum daily quantity of fibrous feed, and that the fibre can be supplied as roughage or feed, but does not indicate the type of feed which can be administered to veal calves.

The aim of the present study was to determine if solid feeds in addition to the liquid diet of veal calves could satisfy the EU Council regulations and could cause positive effects on the development of ruminal mucosa. An additional goal was to examine ruminal mucosa in relation to the administration of different sources of solid feeds, a concentrate that was pelleted or extruded, and corn silage or dried corn silage, because different quantities and types of dietary fibres may differently affect the ruminal mucosa and its development (Mertens, 1992). In this paper we will examine in parallel the histological aspects and histometrical parameters of ruminal mucosa in calves fed milk replacer only and in calves in which the milk replacer was supplemented with 4 different solid feeds.

Materials and methods

Animals and dietary treatments

Twenty-five Holstein calves, imported from Poland, (2 weeks old; 60±6 kg live weight) were randomly assigned to 5 groups (n=5 calves each) and housed in five sheds, tethered in individual crates. The calves of the control group (C) received a traditional milk replacer only. The calves of the other four groups received a concentrate feed, pelleted (T1) or extruded (T3), and corn silage (T2) as well as dried corn silage (T4). In this way we tested the effect of feeds with a high fibre content, corn silage administered dried (T4) or with high moisture (as fed) level (T2), and feeds with a low fibre content, the concentrate feeds. In addition, we tested the effect of different treatments of the concentrate feed, both the one aimed at obtaining pelleted form (T1) and the one aimed at obtaining extruded form (T3), both procedures which should enhance nutrient availability. Table 1 shows chemical composition of the different diets.

Milk replacer consumption was equal in all five groups. Solid feeds were fed from the third week of age and were given daily in individual buckets after milk distribution. The amounts of solid feeds ranged from 60 g/d at the beginning of the study to 250 g/d at the end of it (according EU Council prescriptions). The health conditions of the calves were noted daily during the solid feed distribution. The incidence of ruminating behaviours was in addition noted. The ruminating behaviour was observed according Martin and Bateson (1986). The trial lasted 158 days.

Gross-anatomical and microscopic examination of rumens

At the end of the trial, the calves were conducted to the slaughterhouse. At slaughter (224±15 kg live weight), the gastrointestinal apparatus was promptly excised from the carcass. The rumen, after being separated from the remaining alimentary canal, was opened along its dorsal margin, and any ruminal lesion was noted and described. Small samples (1 cm³) were promptly excised from the saccus dorsalis (2 cm anterior

to the left dorsal coronary pillar) and saccus ventralis (2 cm anterior to the left ventral coronary pillar) of each rumen. These samples were excised 2 cm dorsally to the right accessory pillar, and respectively 2 cm ventrally to the right longitudinal pillar (total number of samples n = 50). These samples were immediately fixed in 4% paraformaldehyde in phosphate-buffered saline (PBS), pH 7.6, for 24 h at 4 °C for histological, histopathological and histometric examinations. The samples were subsequently treated for cryoprotection with 20% sucrose in PBS for 3 h at 4 °C and frozen in isopentane cooled in liquid nitrogen. Ten µm-thick serial sections were then cut on a cryostat, stained with hematoxylin and eosin (HE) and examined under the light microscope. For histometry, five ruminal papillae from each section were examined and measured (in µm) considering their length and epithelium depth. The length of ruminal papillae was measured from the base to the apex. The epithelium depth of ruminal papillae was measured from the basal to the superficial layer. Both measurements were taken at 200x utilizing an Olympus BX51 photomicroscope, equipped with a DP software for the image analysis (Olympus, Italy). In addition we have calculated (at 40x) the number of ruminal papillae per cm² of mucosa. The histological and histometrical examinations were conducted in a blind way.

Statistical analysis

The data were analysed by ANOVA using the General Linear Models procedure of the SAS Institute, Inc. (1985).

Results

Gross-anatomical characteristics of rumens

All the calves were in good healthy conditions during the entire trial. The calves fed solid feeds added to the milk replacer showed ruminating behaviour from 2 months of age, independently of the type of feed.

Gross examination of rumens revealed that the mucosa was much darker in animals whose diets had been supplemented with solid feeds than in control veal

Table 1. Chemical compositions of milk replacer, dried corn silage, corn silage and pelleted or extruded feed used in the study (as fed).

| ITEM | MILK REPLACER | | CORN SILAGE | DRIED CORN SILAGE | PELLETED OR EXTRUDED FEED |
|----------|---------------|-----------|-------------|-------------------|---------------------------|
| | 0-6 weeks | > 6 weeks | | | |
| CP | 25.50 | 22.69 | 3.10 | 8.08 | 17.19 |
| NDF | 0.99 | 0.79 | 16.10 | 41.96 | 17.19 |
| NSC | 21.16 | 20.66 | 6.80 | 17.93 | 39.49 |
| Fat | 17.59 | 20.59 | 0.90 | 2.52 | 4.99 |
| Ash | 6.99 | 7.49 | 1.32 | 3.44 | 7.19 |
| Fe (ppm) | 59.50 | 9.77 | 60.72 | 158.24 | 82.42 |

CP: crude protein; NDF: neutral detergent fibre; NSC: not-structural carbohydrates.

Solid feeds and the calf rumen

(Fig. 1). Furthermore, the rumens of animals given solid feeds (T1-T2-T3) had areas of hyperaemia and scar formation, and showed the presence of catarrhal exudate. Areas characterised by wall thickening and absence of papillae were in addition present. Finally, keratinous filaments were also frequently detectable in the rumen wall. In calf rumens of the T4 group the aspects above described were negligible, and we could never observe keratinous filaments. The rumens of the calves fed milk replacer only were normal in their aspect.

Microscopic characteristics of rumens

Microscopic examination of the rumens of animals fed milk replacer showed that ruminal histology was mainly without substantial changes (Fig. 2), although the following unusual features were occasionally evident: i) a heavily acidophilic stratum corneum of some ruminal

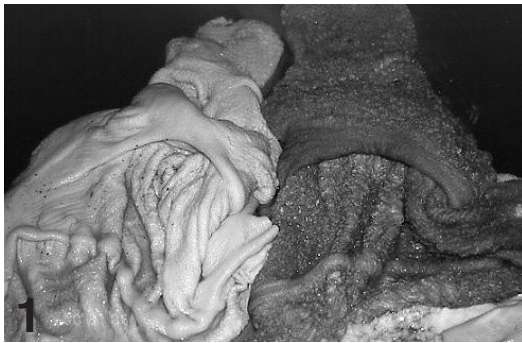

Fig. 1. Macroscopic appearance of ruminal mucosa from calves fed milk replacer only (left), and fibrous feed (right). Note the darkened mucosa in the fibre-fed animal.

papillae; ii) a slight hyperkeratinization of other ruminal papillae; and iii) a limited excess of exudate in the lumen (Fig. 3). These features were more evident in the saccus ventralis than the saccus dorsalis.

The rumens of calves given pelleted feed, corn silage, and extruded feed (T1-T2-T3) always showed features of chronic ruminitis with no detectable differences between the dorsal and ventral saccus. The specific features were: (i) Presence of large quantities of catarrhal exudate in the lumen (Fig. 4). (ii) Presence of conical ruminal papillae which consisted exclusively of a heavily acidophilic stratum corneum (Fig. 5). (iii) Presence of a stratum corneum which showed an abnormally coloured and filamentous appearance in numerous ruminal papillae (Fig. 6). The filaments were often wholly to partly detached from the epithelium, and probably corresponded to the keratinous filaments gross-anatomically observed (see above). (iv) Presence of short and conical ruminal papillae with an enlarged base showing an evident inflammatory infiltration (Fig. 7). (v) Presence of ruminal papillae with unusual shapes (Figs. 8, 9). Some papillae were very thin (Fig. 8), some others were thin at their base, and enlarged and branched at their apex (Fig. 9).

In calves fed pelleted feed (T1) the recurrent ruminal lesions were: i, ii, iii, and iv. In calves fed corn silage (T2) the recurrent ruminal lesions were: i, iii, and v. In calves fed extruded feed (T3) the recurrent ruminal lesions were: i, iii, and v.

When calves were given dried corn silage, their rumens showed focal hyperkeratinization, and focal hypertrophy of papillary epithelium (Fig. 10). In the cases of focal hyperkeratinization, the superficial cells of the stratum corneum were sometimes swollen and detached (parakeratosis; Fig 11). These cells probably correspond to the corneal cells of type C described in

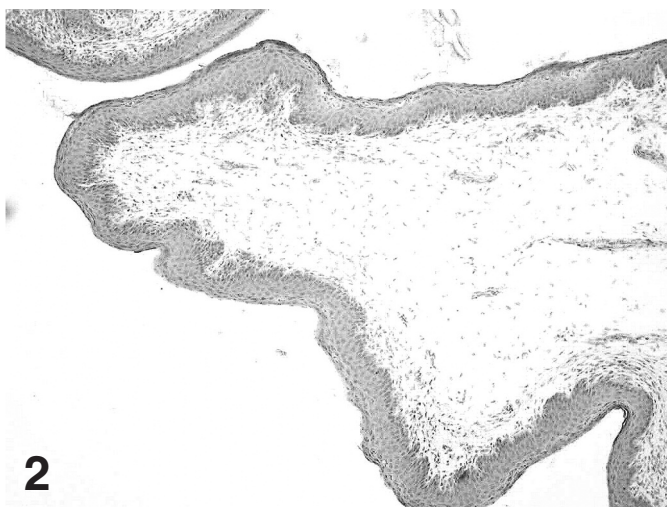

Fig. 2. Control, milk replacer: an anatomically normal aspect of the ruminal mucosa. x 100

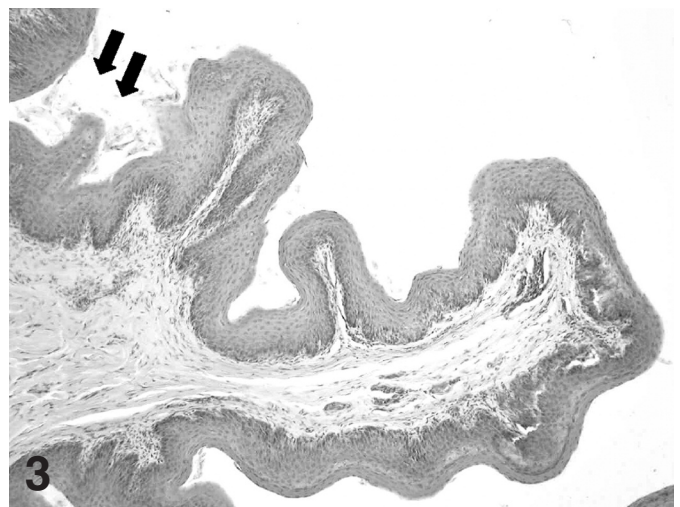


Fig. 3. Control, milk replacer: a limited excess of exudate is present in the lumen (arrows). x 100

Zitnan et al. (1999). There was a negligible presence of exudate in the lumen.

Histometry

Both the mean length of ruminal papillae and mean thickness of the papillary epithelium were higher in calves given milk replacer only than in calves whose diets were supplemented with fibrous feeds, as shown in

Table 2, even if results were not statistically significant ($P > 0.05$). Mean papillary length in animals fed both corn silage (T2) and extruded feed (T3) was higher than in animals fed pelleted feed (T1) and dried corn silage (T4). The values of the epithelial thickness were nearer in the ruminal mucosa of the calves of T1, T3, and T4 groups, whereas this parameter was evidently lesser in calves fed corn silage (T2). The number of ruminal papillae per cm^2 of mucosa is shown in Table 2. This

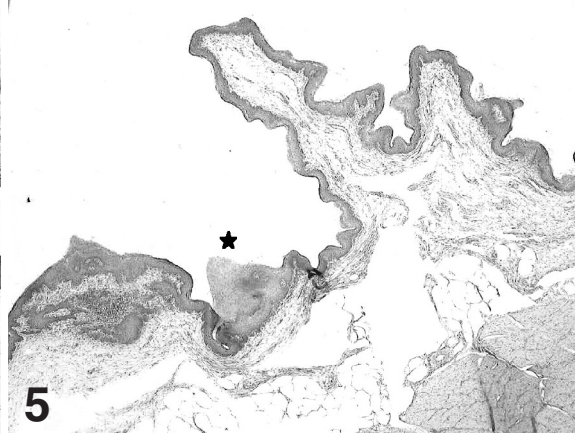
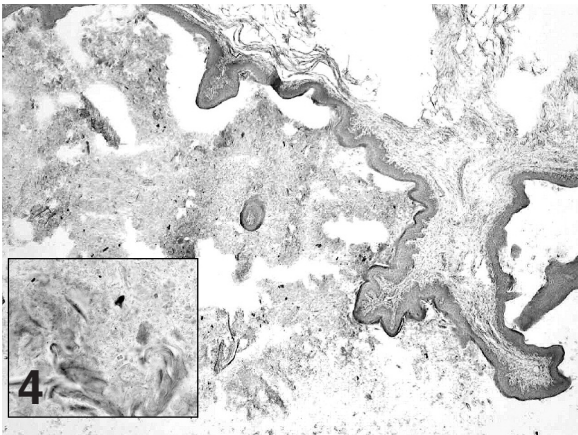


Fig. 4. Pelleted feed (T1): a large quantity of catarrhal exudate is detectable in the lumen. x 40.

Insert: the aspect of the exudate is shown at higher magnification. x 400

Fig. 5. Pelleted feed (T1): a chronic ruminitis is indicated by the presence of a conical ruminal papilla made up of a heavily acidophilic stratum corneum (asterisk). x 40

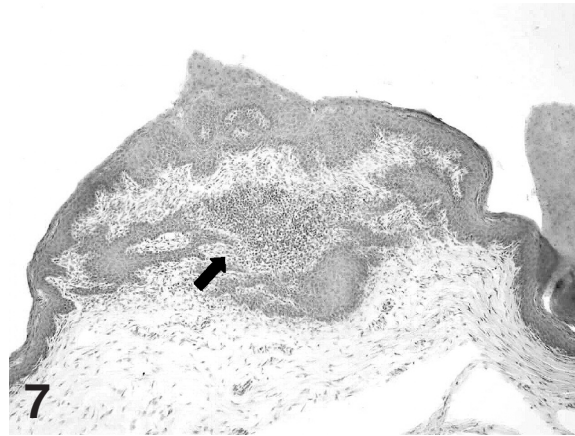
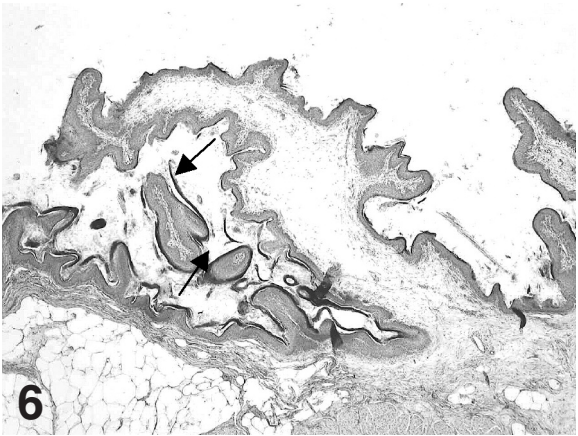


Fig. 6. Pelleted feed (T1): a chronic ruminitis is indicated by an abnormally coloured stratum corneum, filamentous in its appearance (thin arrows). x 40

Fig. 7. Pelleted feed (T1): the enlarged base of a short papilla shows a marked inflammatory infiltration (arrow). x 100

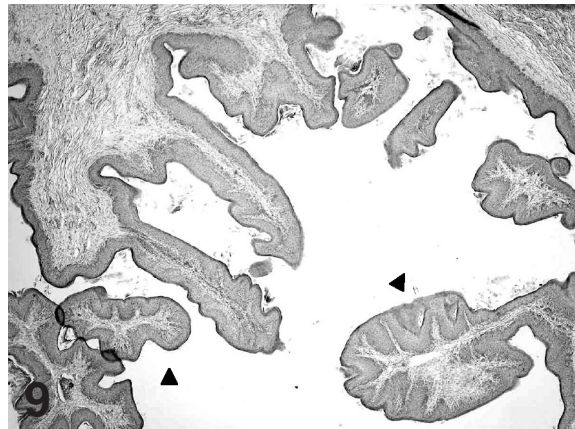
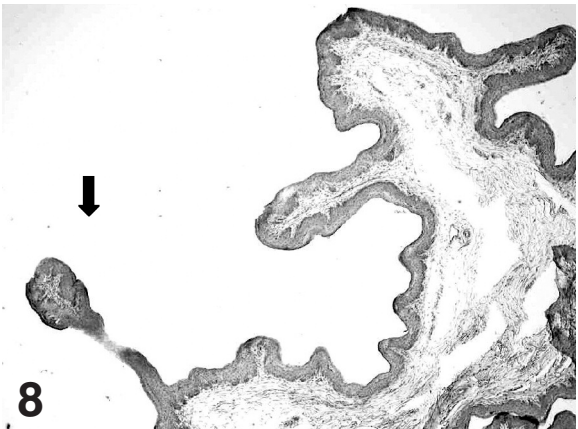


Fig. 8. Corn silage (T2): a ruminal papilla is abnormally thin (arrow). x 40

Fig. 9. Extruded feed (T3): some ruminal papillae are branched in appearance (arrowheads). x 40

Solid feeds and the calf rumen

number was higher in calves given fibrous feeds than in calves given milk replacer only ($P < 0.01$). In addition, in the calves given the pelleted feed (T1) and dried corn silage (T4) the difference was statistically significant ($P < 0.05$).

Discussion

The morphological and morpho-functional consequences of solid feeds administered as supplements of the milk replacer diet were marked on the ruminal mucosa of the veal calves examined in this trial.

The ruminal mucosa of all the animals given solid feeds was much darker than that of animals given milk replacer only. This is due to the digestion of carbohydrates present in solid feeds and the consequent production of volatile fatty acids (Morisse et al., 1997).

The gross-anatomical and microscopical examination of the rumens are in good accordance.

In animals given milk replacer only, the rumen was mainly normal although slight signs of catarrhal ruminitis were occasionally present, above all in the ventral sac of the rumen, probably due to the more prolonged presence of the milk replacer in it. It is known that the presence of milk replacer in the rumen of veal calves can (i) modify the ruminal mucosa and (ii) induce an inflammation of variable severity. These problems are probably due to the failure of the reticular groove reflex resulting in ruminal "drinking" (Breukink et al., 1988; Buisman et al., 1990; Lalles and Toullec, 1999). The animals of this trial were bucket-fed, so they could not

properly extend their necks. This probably reduced the reticular groove motility, thus promoting ruminal drinking.

The rumens of animals given pelleted feed, corn silage, and extruded feed always showed signs of chronic catarrhal ruminitis associated with hyper/parakeratosis, probably due to the mechanical and abrasive action of the solid feeds on the mucosa of a "physiologically monogastric" animal, as Marounek et al. (1992) and Greenwood et al. (1997) have observed, evidencing low concentrations of rumen metabolites and consequent limited rumen fermentation in veal calves. The large quantities of catarrhal exudate found in the lumen of the rumens in these animals were probably due to water retention caused by lactic acid in excess, arising in turn from the high starch content of the solid feed. Dshurov (1976) has thoroughly described the morphological changes in the ruminal mucosa associated to ruminal acidosis, and our results are in part in accordance with his description. In addition, other Authors (McGavin and Morrill, 1976; Nocek et al., 1984; Zitnan et al., 1998) have evidenced ruminal lesions which were similar to those here described in calves fed concentrate. It must be stressed now that in spite of the very high frequency of ruminal lesions commonly observed in these veal calves, their health conditions remained generally without alteration. Morisse et al. (2000) have recently made similar observations.

The rumens of calves given dried corn silage were mainly normal although areas containing foci of

Table 2. Effect of the diet on papillary length (mm), epithelial thickness (mm), and number of papillae per cm^2 , in veal calves.

| | CONTROL | PELLETED FEED | EXTRUDED FEED | CORN SILAGE | DRIED CORN SILAGE | SEM |
|------------------------------------|------------------|--------------------|-------------------|--------------------|--------------------|-------|
| Papillae length, mm | 1765 | 1411 | 1558 | 1519 | 1386 | 158.6 |
| Epithelial thickness, mm | 77.58 | 72.20 | 74.16 | 65.86 | 76.20 | 3.12 |
| Nr. of papillae, per cm^2 | 8.6 ^A | 13.6 ^{Ba} | 11.5 ^B | 12.12 ^B | 11.0 ^{Bb} | 0.80 |

A, B: Means within a column with unlike superscripts differ ($P < 0.01$). a, b: Means within a column with unlike superscripts differ ($P < 0.05$).

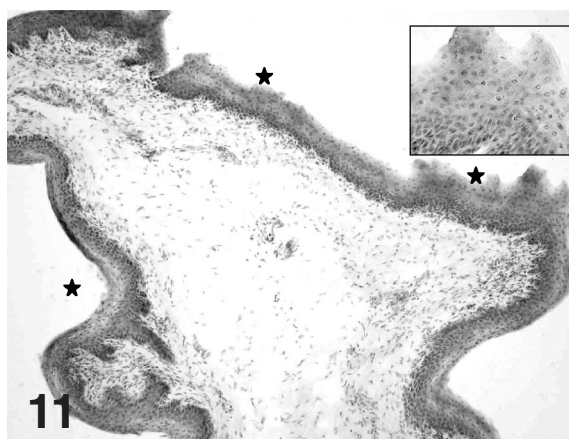
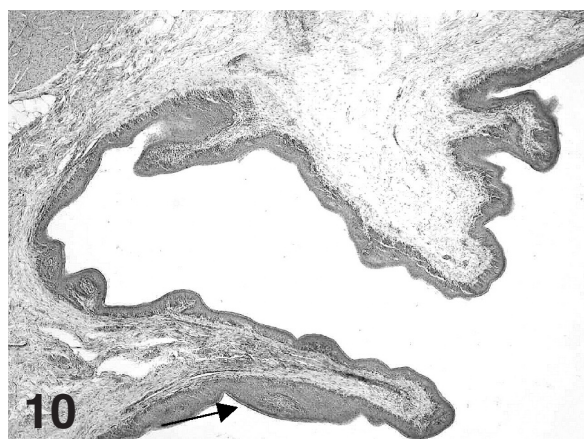


Fig. 10. Dried corn silage (T4): focal areas of hyperkeratinization are evident (thin arrow). x 40

Fig. 11. Dried corn silage (T4): superficial cells of the stratum corneum are swollen and detaching (asterisks). x 100; insert, x 400

hyperkeratinization were observed, as well as zones with foci of epithelial hypertrophy of ruminal papillae. The effects of this latter fibrous diet on the calf ruminal mucosa were evidently less negative than those originating from the other fibrous diets of this trial, probably due to both the different moisture content in corn silage and different content of carbohydrates in pelleted and extruded feeds.

Histometry revealed that both mean papillary length and epithelial thickness were higher in the rumens of animals fed milk replacer only than in those ones whose diet was supplemented with solid feeds. Evidently, length of the ruminal papillae decreased as the abrasive force of the diet, linked to the presence of dietary fibres, increased. According to our measurements and consequent interpretation, the dried corn silage is the hardest supplement among those tested by us, but this same fibrous supplement is also the one which induces a higher epithelium thickness, with a value near to the one observed in control veal calves. The epithelium thickness is surely one of the morpho-functional ruminal values which is linked to the efficiency of the epithelium in regulating luminal exchanges, and in particular nutrient absorption. On the contrary, in calves fed corn silage this value was lesser than in the other groups. This possibly has a relation with the extensive inflammatory status accompanied by detaching of filaments from the stratum corneum, which is very frequent in this type of diet. The evaluation of the mean number of ruminal papillae per cm² of mucosa reveals that animals fed milk replacer only show a lesser number compared with animals fed fibrous feeds. Limited to this histometrical aspect, we can agree with the statement of a lesser morpho-functional development of ruminal mucosa in veals fed milk replacer only (Scientific Veterinary Committee, Report on the welfare of the calves, 1995). A limited knowledge exists about the histometry of the rumen mucosa in veal calves whose liquid diet was variously supplemented (Greenwood et al., 1997; Kohler et al., 1997; Morisse et al., 1999; Zitnan et al., 1999; Cozzi et al., 2002), but these latter results are difficult to put into proper relation with those here presented, possibly due to the different types of solid feeds used in the trials. Physical form of the fibrous diet also surely affects the structural pattern of ruminal mucosa (Beharka et al., 1998).

This present histological and histometrical study shows that dried corn silage supplement of the milk replacer diet is less detrimental for the ruminal mucosa than the other three types of fibrous dietary supplementation.

These morpho-functional results are in agreement with the producing parameters evidenced by us in one other paper (Dell'Orto et al., 2002), which shows that the average daily weight gain was not affected in the group of veal calves whose diet was supplemented with dried corn silage. We can thus underline that the good, even if not very good, morpho-functional pattern of the rumen mucosa which comes from a satisfactory solid feed

supplementation is accompanied by no detrimental effects on the performances of veal calves. From a general point of view, all the dietary supplementation we have tested appear able to promote the ruminating behaviour, thus mimicking in some way the natural condition of young ruminating animals, as are veal calves. However, all the dietary supplementation appear to induce, to a variable degree of severity, ruminal lesions, and among them, the dried corn silage supplement appears, until now, a good compromise between the welfare of veal calves and the needs of the veal calf industry. Our final consideration is that the best solid feed supplementation in the milk replacer diet, so that it may be able to improve digestive processes and does not cause injuries to ruminal mucosa, has not yet been found.

Acknowledgements. This work was supported by grants of the University of Milan (First, 2001). The authors want to thank Mr. Renato Bonassi, owner of the farming in Calvisano (BS, Italy).

References

- Beharka A.A., Nagaraja T.G., Morrill J.L., Kennedy G.A. and Klemm R.D. (1998). Effects of form of the diet on anatomical, microbial, and fermentative development of the rumen of neonatal calves. *J. Dairy Sci.* 81, 1946-1955.
- Breukink H.J., Wensing T., Van Weeren-Keverling Buisman A., Van Bruinessen-Kapsenessen E. and De Visser N.A. (1988). Consequences of failure of the reticular groove reflex in veal calves fed milk replacer. *Vet. Quart.* 10, 126-135.
- Broom D.M. (1991). Needs and welfare of housed calves. In: *New trends in veal calf production*. EAAP Publ. No. 52, Pudoc, Wageningen, The Netherlands. pp 23-31.
- Buisman A., Van Wensing W.K., Ingh T.S.G.A.M. and Breukink H.J. (1990). Intraruminal administration of milk in the calf as a model for ruminal drinking: clinical aspects and biochemical and morphological changes in the rumen. *J. Anim. Physiol. An. Nutr.* 63, 255-266.
- Cozzi G., Gottardo F., Mattiello S., Canali E., Scanziani E., Verga M. and Andrighetto I. (2002). The provision of solid feeds to veal calves: I. Growth performance, forestomach development, and carcass and meat quality. *J. Anim. Sci.* 80, 357-366
- Dell'Orto V., Paratte R., Di Giancamillo A., Sgoifo Rossi C.A., Bontempo V., Agazzi A., Domeneghini C. and Savoini G. (2002). Influence of fibrous supplements on rumen morphology and production parameters in veal calves. ASAS (American Society of Animal Science) 1st Joint International Meeting, Quebec City, July 2002.
- Dshurov A. (1976). Über die Dynamik der morphologischen Veränderungen bei der Pansenazidose der Mastkalber. *Deut. Tierärztliche Wochenschrift.* 83, 403-407.
- EU Council (1991). 91/629EC Directive. Official Journal of the European Communities. 11 December, No. 340/28, Bruxelles, Belgium.
- EU Council (1997). 97/2/EC Directive. Official Journal of the European Communities. 28 January, No. 25/24, Bruxelles, Belgium.
- Greenwood R.H., Morrill J.L., Titgemeyer E.C. and Kennedy G.A. (1997). A new method of measuring diet abrasion and its effect on the development of the forestomach. *J. Dairy Sci.* 80, 2534-2541.
- Kohler P., Kallweit E., Henning M. and Flachowsky G. (1997).

Diabetes gastroenteropathy

- Comparative examination of rumen development, fattening performance and carcass quality in veal calves from natural maternal rearing or conventional bucket-feeding (German). *Zuchtungskunde*. 69, 254-267.
- Lalles J.P. and Toullec R. (1999). Some aspects of nutrition and health in preruminant calves. In: *Production diseases in farm animals*. 10th International Conference 1998. Wageningen Pers. Wageningen The Netherlands. pp113-123.
- Marounek M., Skrivanova V., Machanova L. and Markalous E. (1992). Weight gains, conversion of nutrients, digestibility of feed and rumen parameters in veal calves (Czech). *Zivocisna vyroba*. 37, 547-554.
- Martin P. and Bateson P. (1986). *Measuring behaviour*. Cambridge University Press, London. pp 55-63.
- McGavin M.D. and Morrill J.L. (1976). Scanning electron microscopy of ruminal papillae in calves fed various amounts and forms of roughage. *Am. J. Vet. Res.* 37, 497-508.
- Mertens D.R. (1992). Nonstructural and structural carbohydrates. In: *Large dairy herd management*. Van Horn H.H. and Wilcox C.J. (eds). American Dairy Science Association. Champaign, IL, USA. p 219.
- Miltenburg G.A.J., Wensing T.H., Smulders F.J.M. and Breukink H.J. (1992). Relationship between blood hemoglobin, plasma and tissue iron, muscle heme pigment, and carcass color of veal. *J. Anim. Sci.* 70, 2766-2772.
- Morisse J.P., Huonnic D., Cotte J.P. and Martrenchar A. (1997). Relation between introducing solid feed and welfare of veal calves. Study on the three groups of 21 black pied calves. *Point Vet.* 24, 1385-1387.
- Morisse J.P., Cotte J.P., Huonnic D. and Martrenchar A. (1999). Influence of dry feed supplements on different parameters of welfare in veal calves. *Anim. Welfare*. 8, 43-52.
- Morisse J.P., Huonnic D., Cotte J.P. and Martrenchar A. (2000). The effect of four fibrous feed supplementation on different welfare traits in veal calves. *Anim. Feed Sci. Technol.* 84, 129-136.
- Morrill J.L. (1999) *The Calf: Birth to 12 Weeks*, Large Dairy Herd Management. Savoy (IL, USA). Am. Dairy Sci. Ass. pp 401-410.
- Nocek J.E., Heald C.W. and Polan C.E. (1984). Influence of ration physical form and nitrogen availability on ruminal morphology of growing bull calves. *J. Dairy Sci.* 67, 334-343.
- Report on welfare of calves (1995). Animal welfare section of the Scientific Veterinary Committee. General Directorate of Agriculture VI/B11/2, Brussels.
- Veissier I., Chazal P., Pradel P. and Le Neindre P. (1997). Providing social contacts and social objects for nibbling moderates reactivity and oral behaviors in veal calves. *J. Anim. Sci.* 75, 356-365.
- Zitnan R., Voigt J., Schonhusen U., Wegner J., Kokardova M., Hagemeister H., Levkut M., Kuhla S. and Sommer A. (1998). Influence of dietary concentrate to forage ratio on the development of rumen mucosa in calves. *Arch. Tierernahr.* 51, 279-291.
- Zitnan R., Voigt J., Wegner J., Breves G., Schroder B., Winckler C., Levkut M., Kokardova M., Schonhusen U., Kuhla S., Hagemeister H. and Sommer A. (1999). Morphological and functional development of the rumen in the calf: influence of the time of weaning. 1. Morphological development of rumen mucosa. *Arch. Tierernahr.* 52, 351-362.

Accepted March 3, 2003